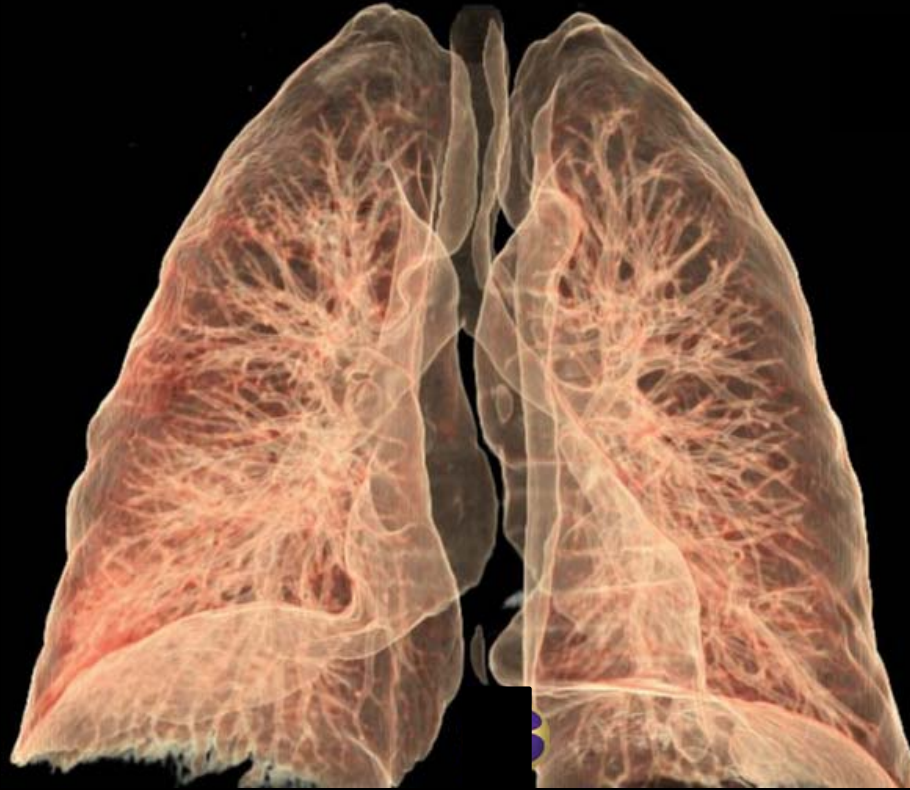

CHEST RADIOGRAPHS: What are you looking at?

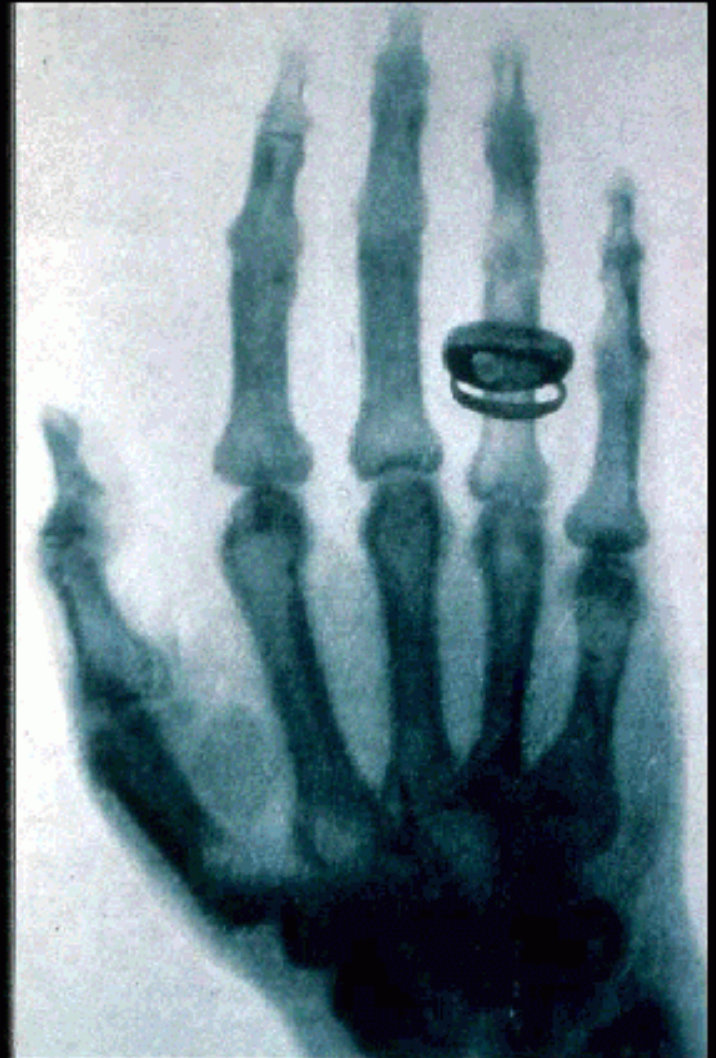

August 23, 2011
Christopher Long, MD, PhD

Lecture objectives

- To introduce a basic approach to looking at a chest radiograph
- To allow correlation between anatomy and radiology


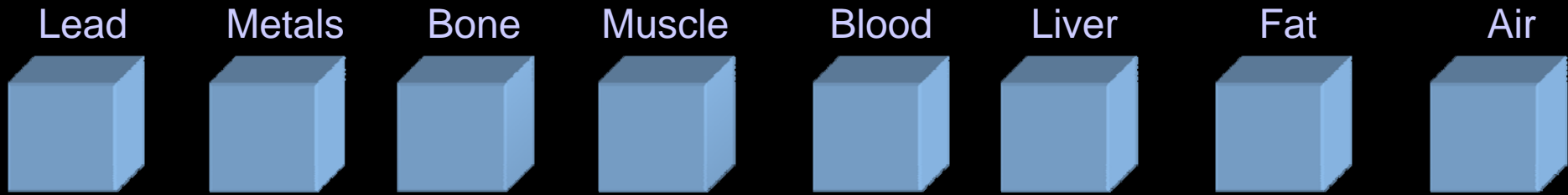
Wilhelm Conrad Röntgen



Wilhelm Conrad Röntgen

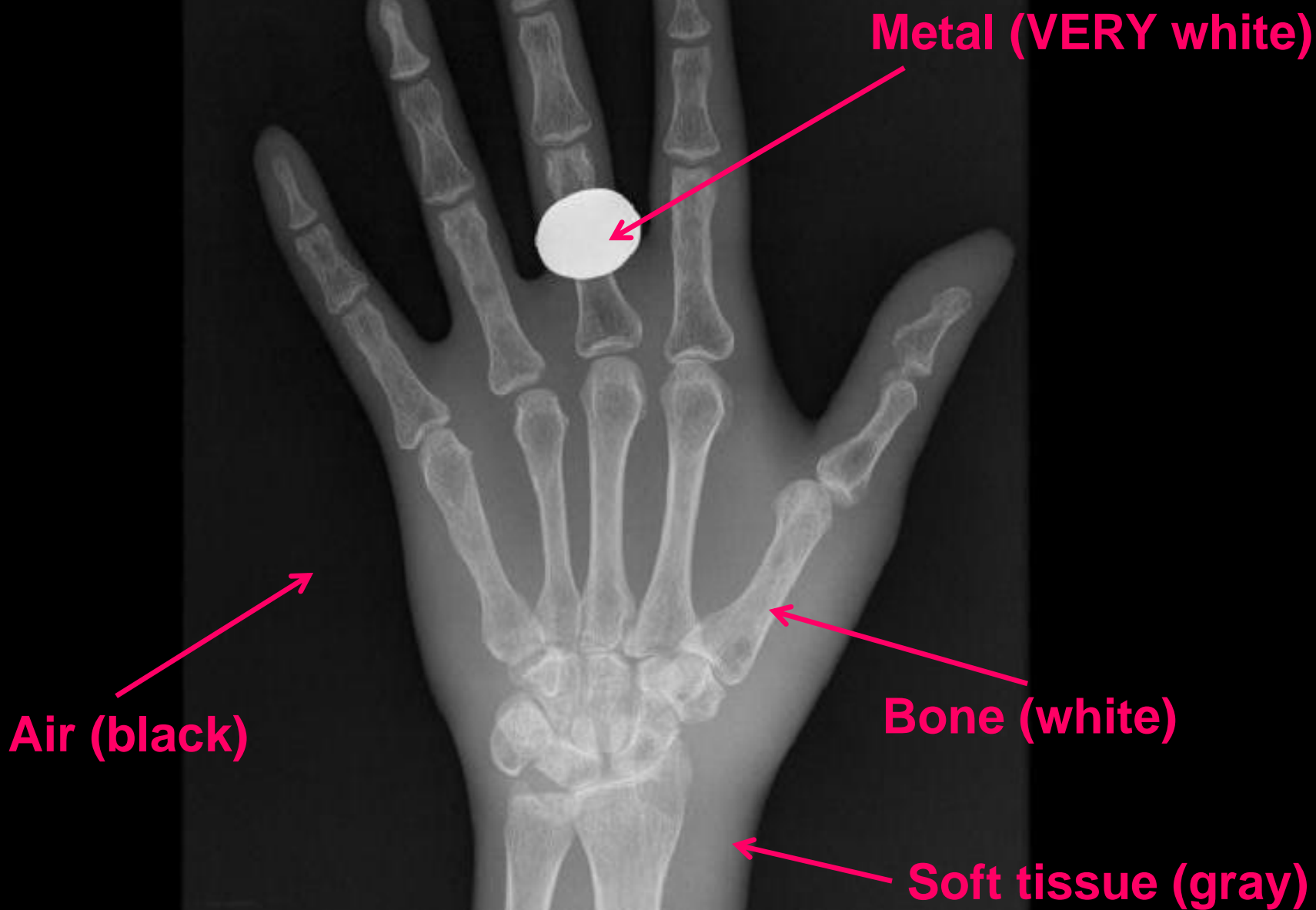


Why is everything BLACK and WHITE?!



WHITE
Radioopaque
"More"
Like Metal

BLACK
Radiolucent
"Less"
Like Air



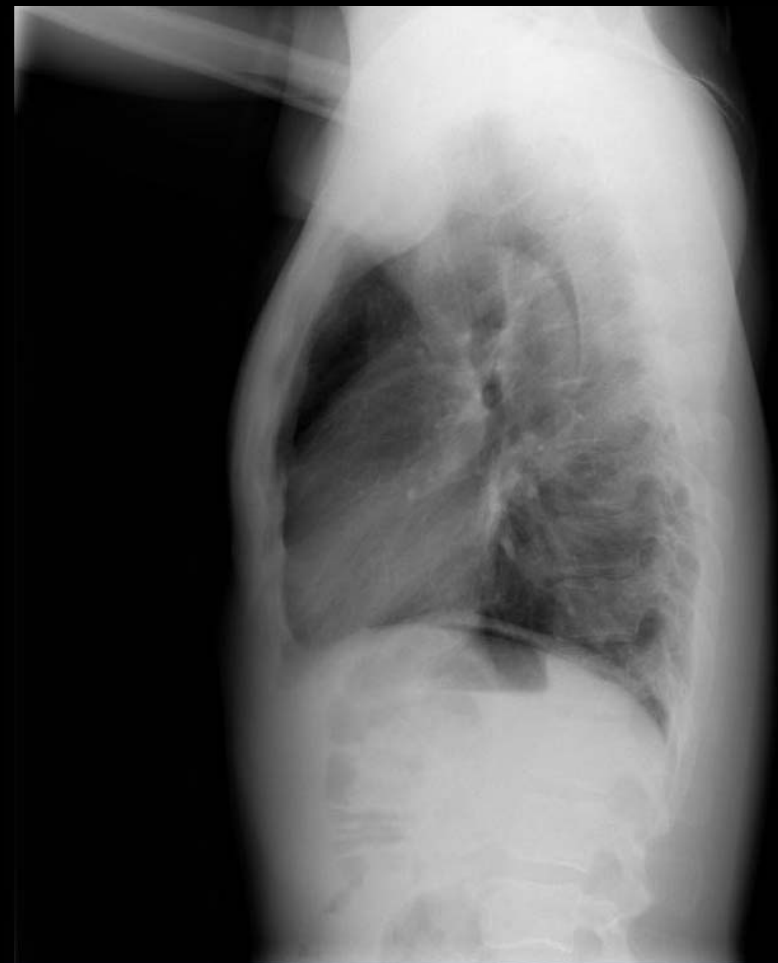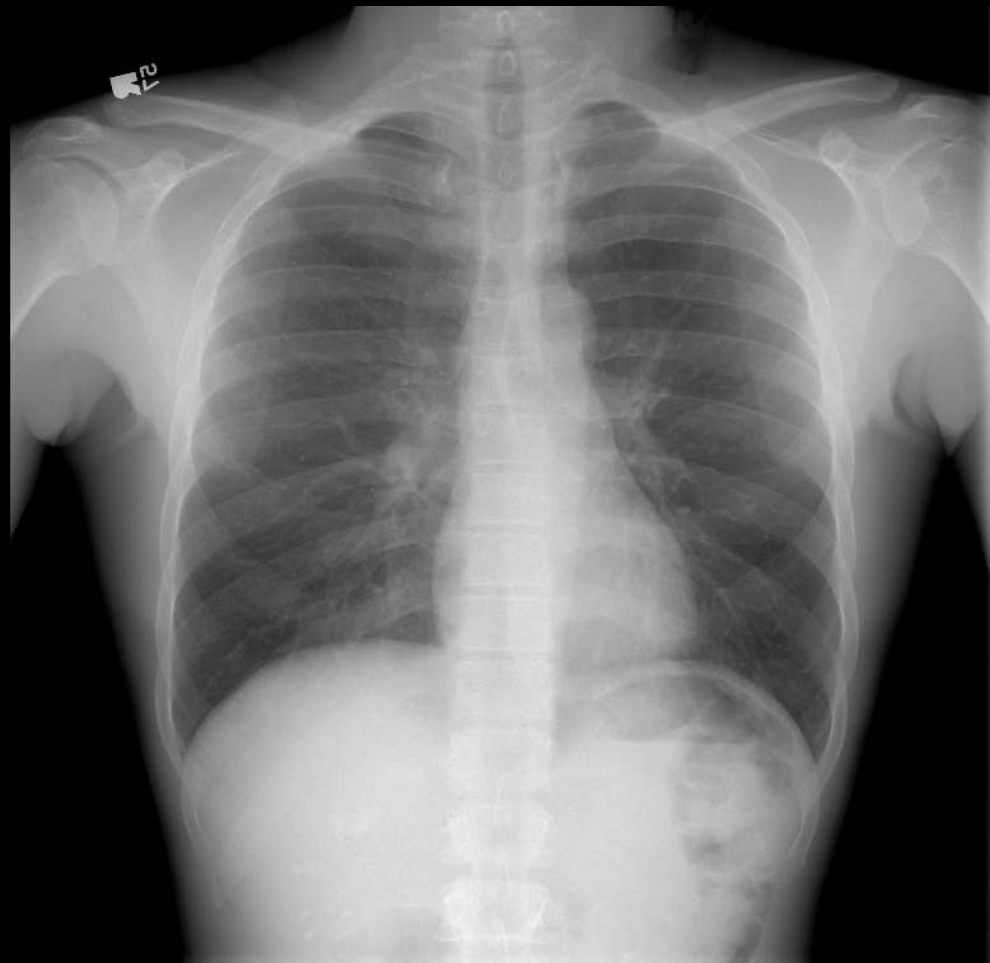
Metal (VERY white)

Air (black)

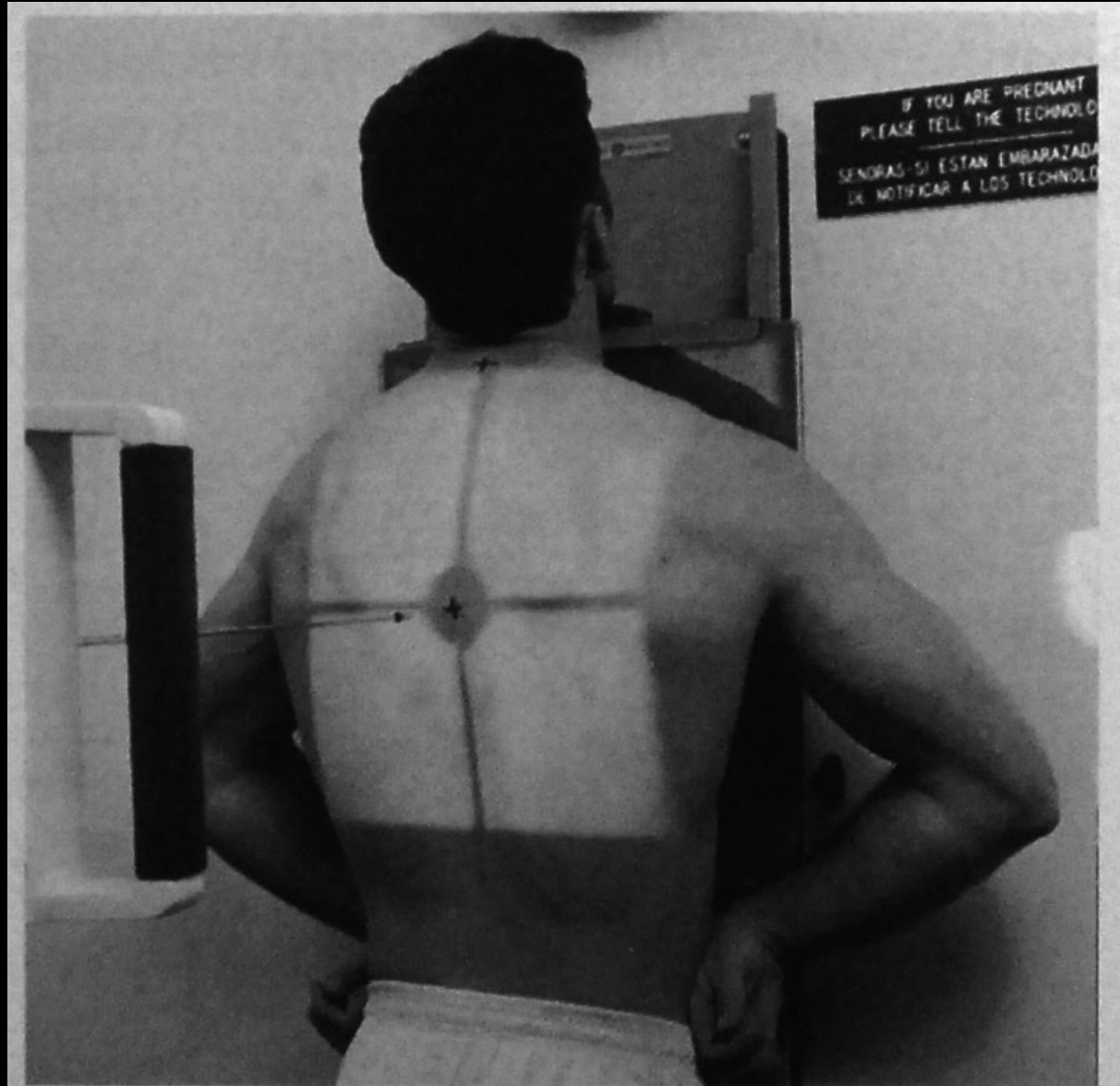Bone (white)

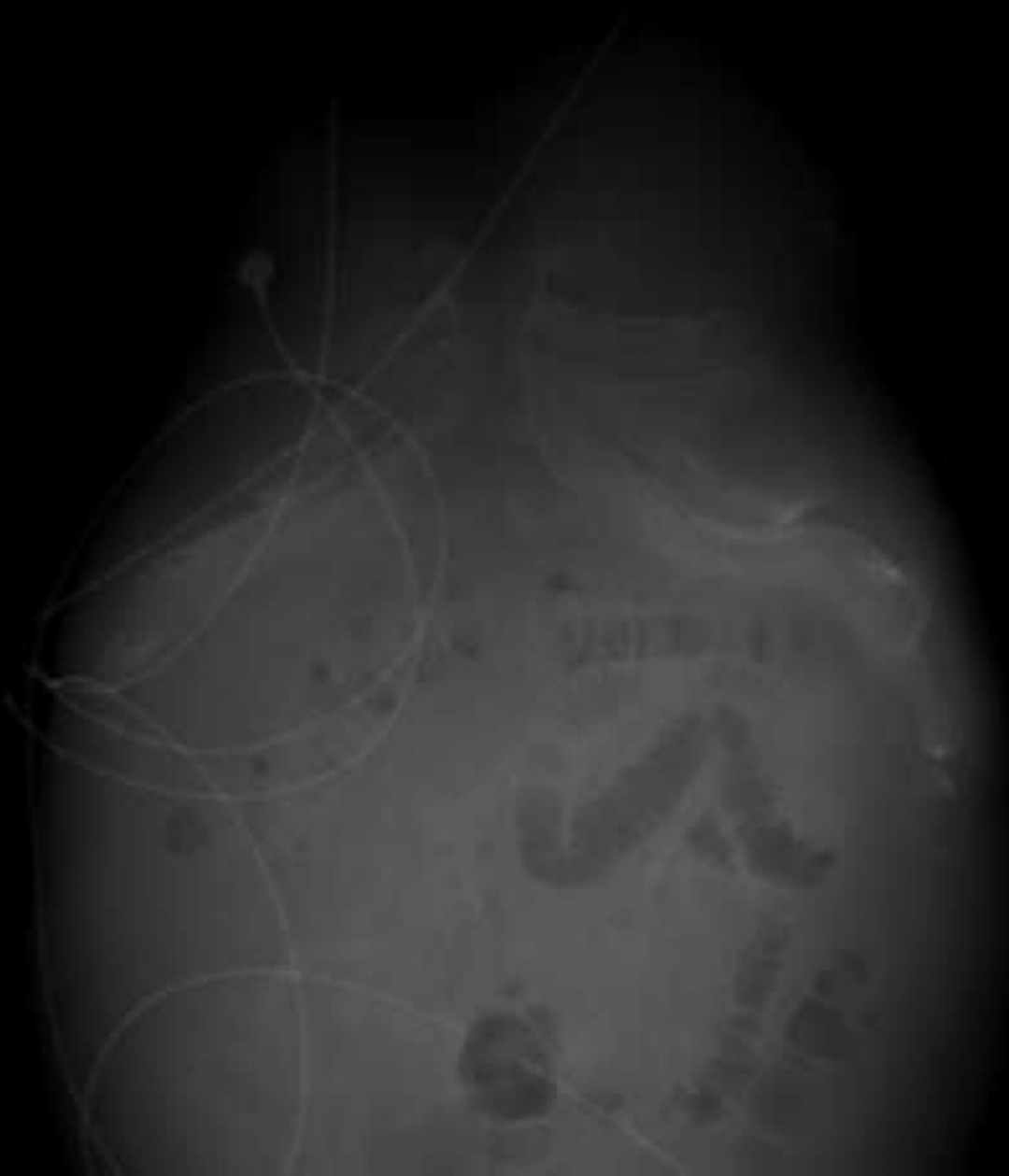
Soft tissue (gray)

The Ideal Study: PA and Lateral Films

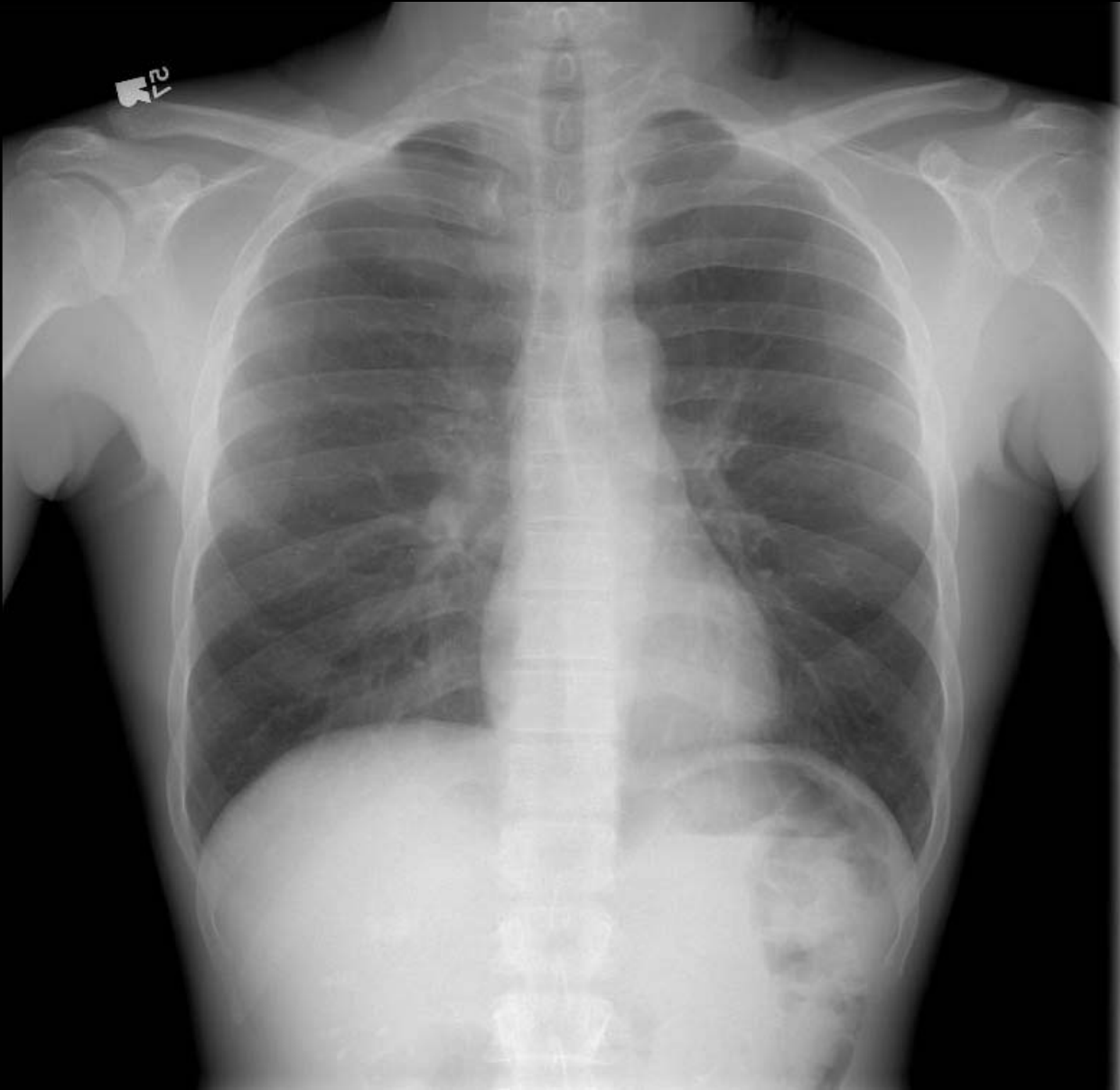


Posterior-Anterior (PA) Radiograph

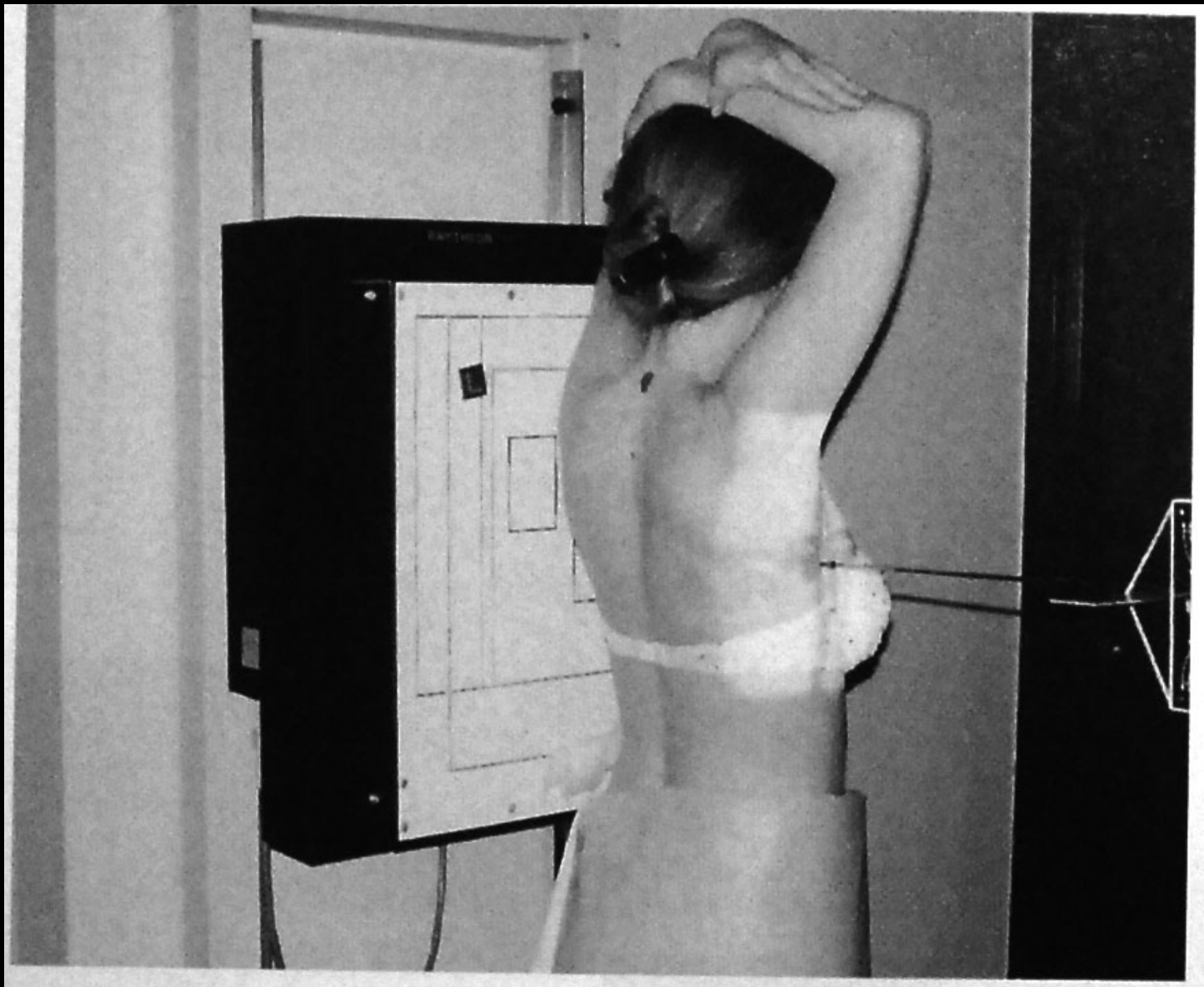


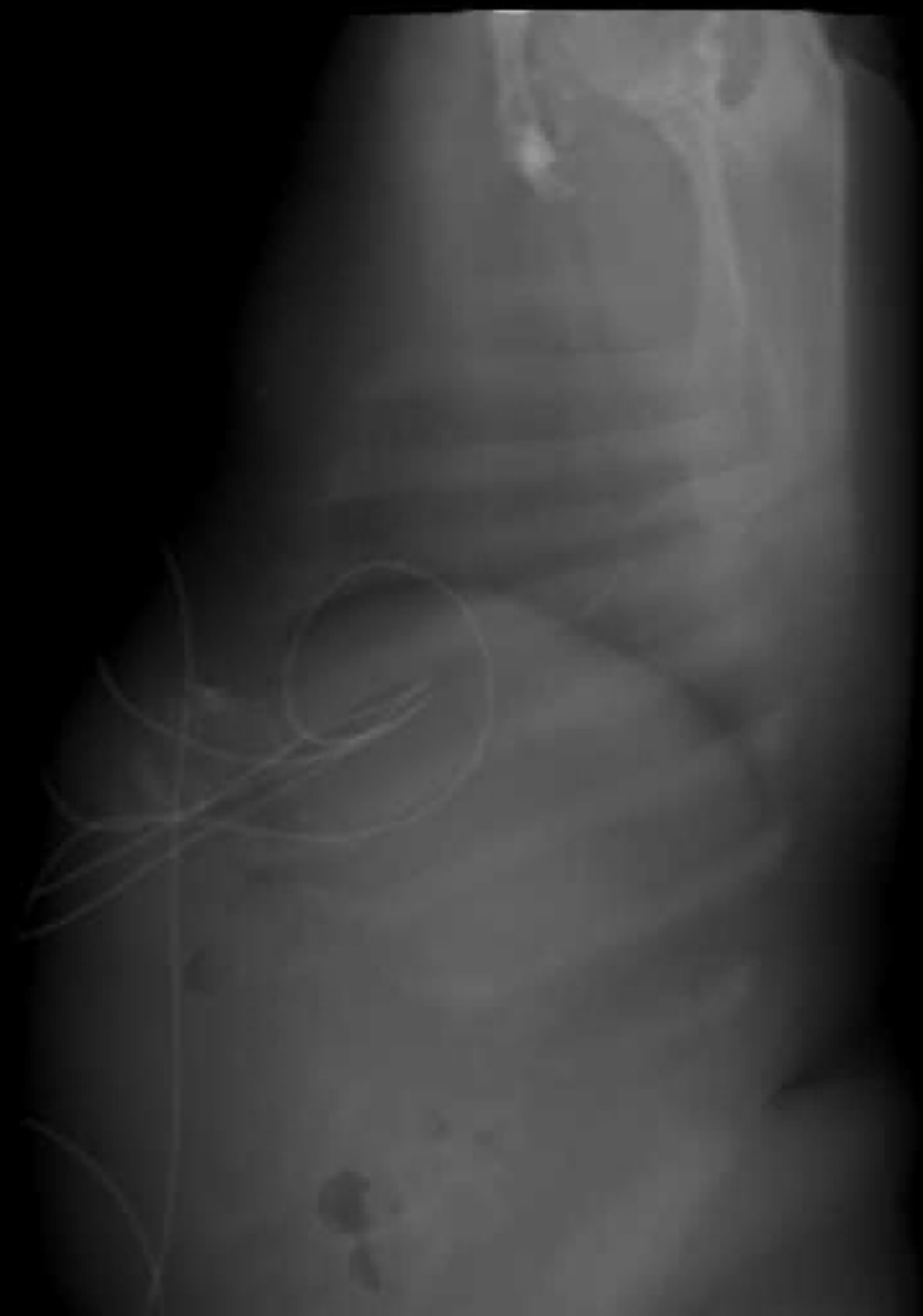

Posterior-Anterior (PA) Radiograph

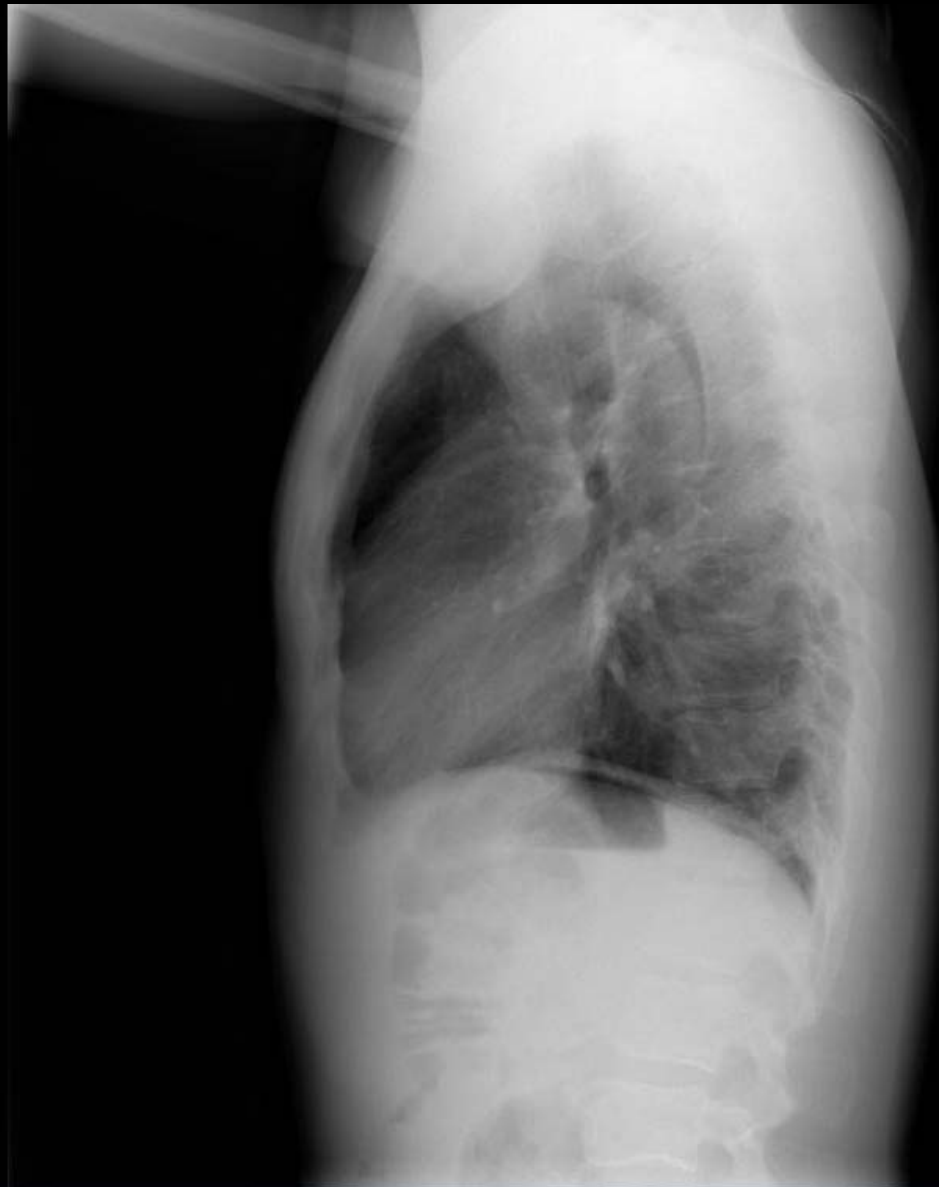

Lateral Radiograph

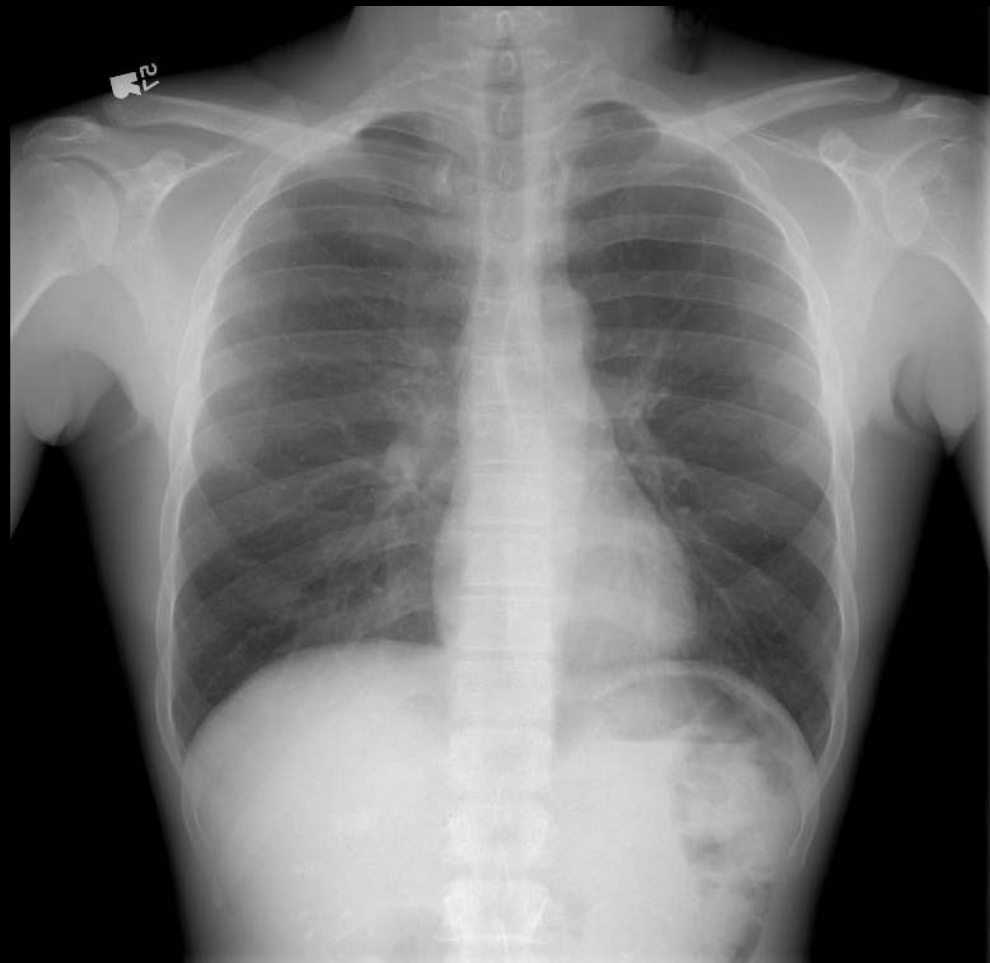




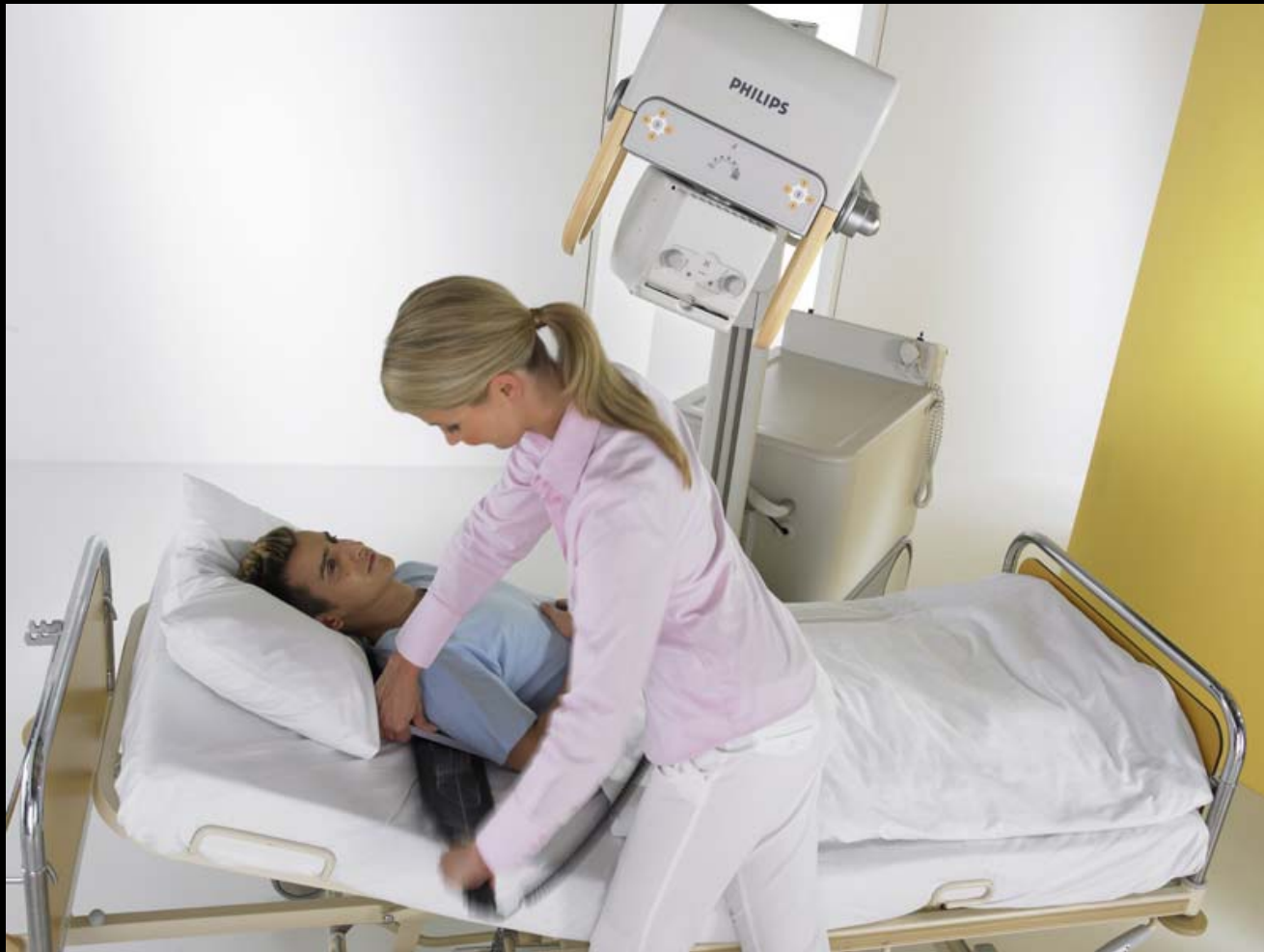Lateral Radiograph



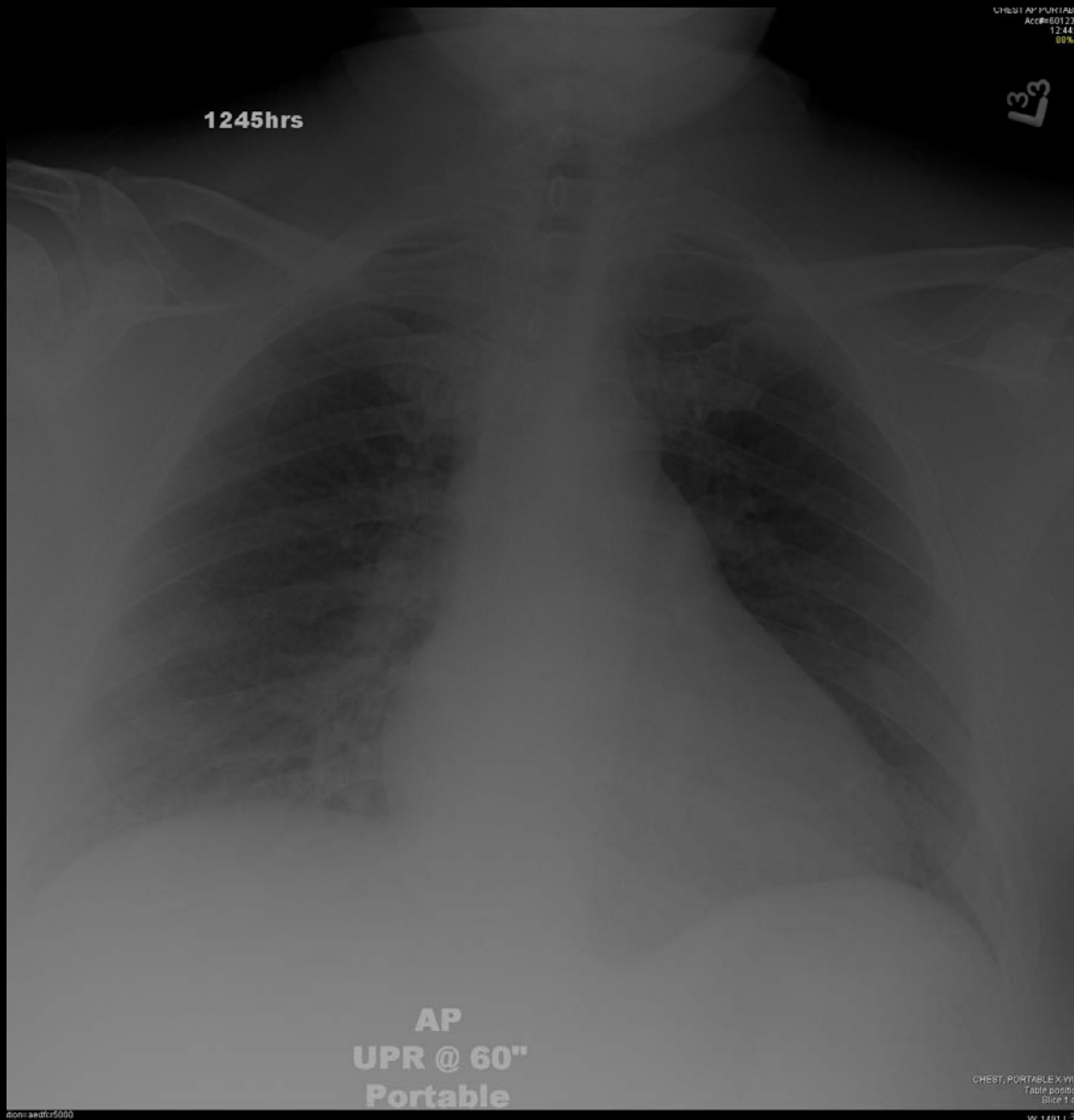
The Ideal Study: PA and Lateral Films



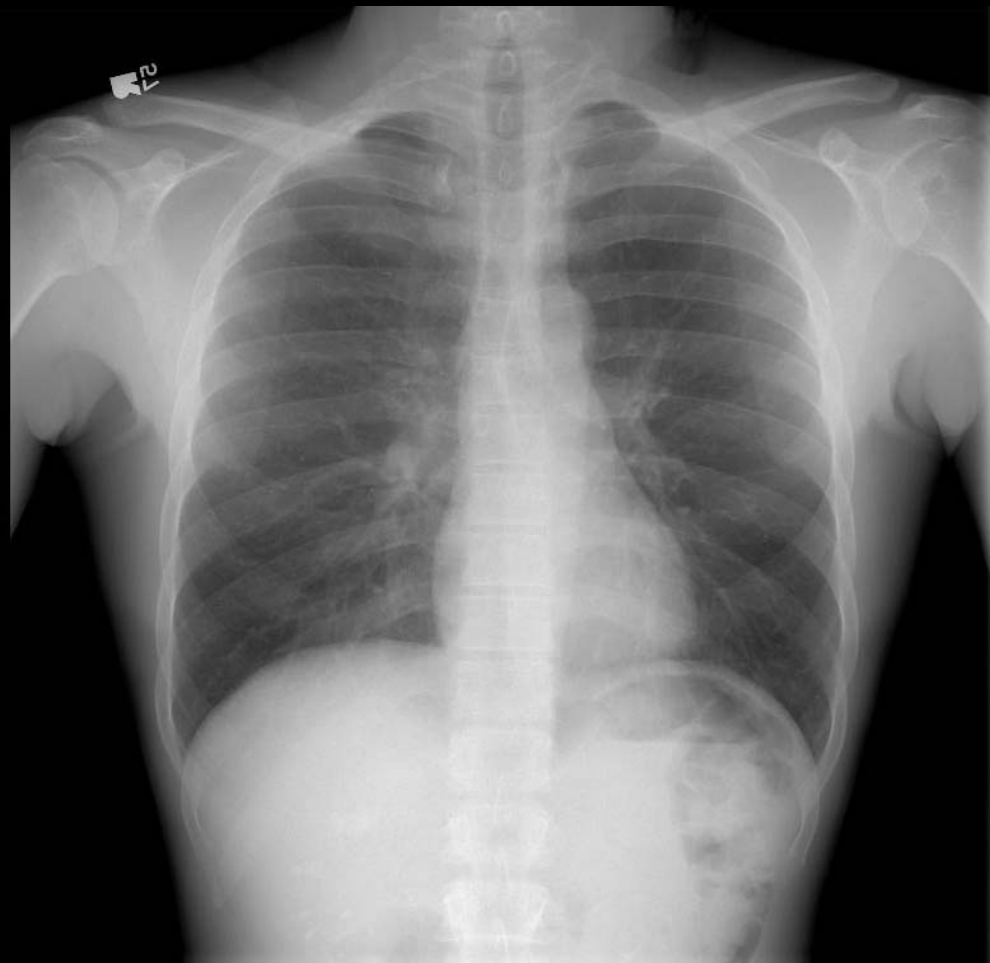
The Reality: AP or Portable Film



The Reality: AP or Portable Film



The Ideal Study: PA and Lateral Films



What are we looking at?

Airway

Bones

Cardiac

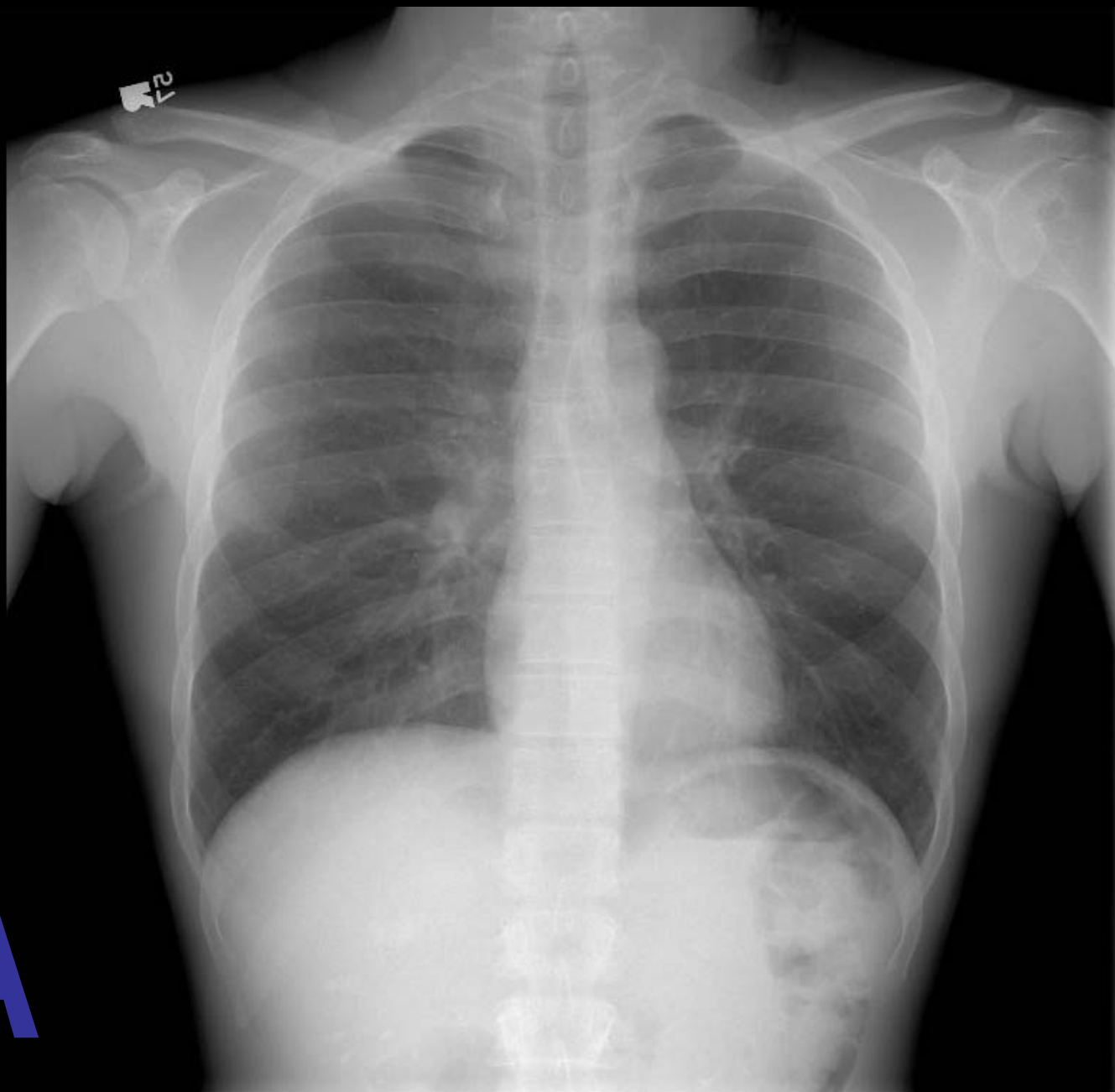
Diaphragm

Effusions

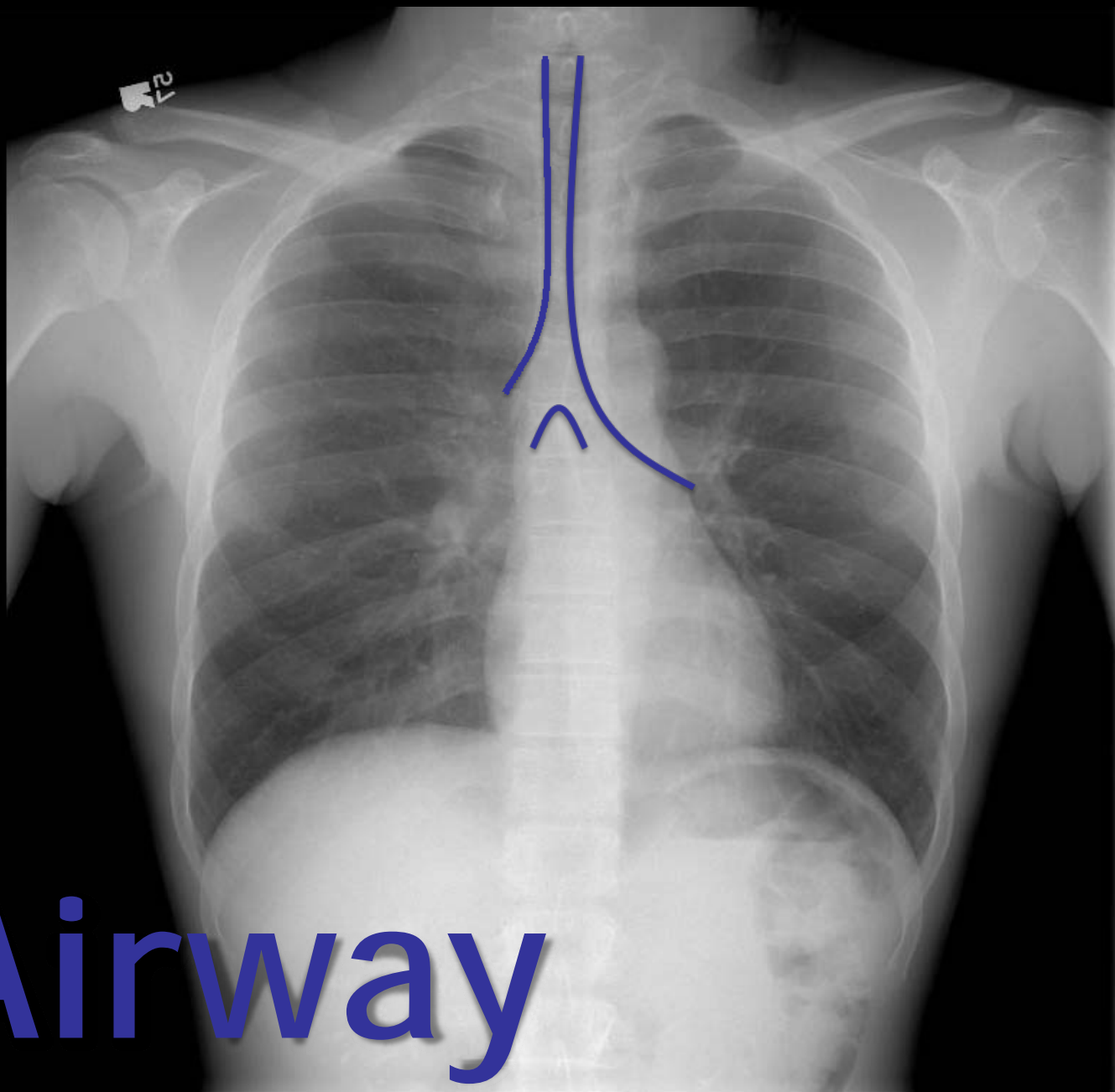
Fields (Lung)

Gastric Bubble

Hardware

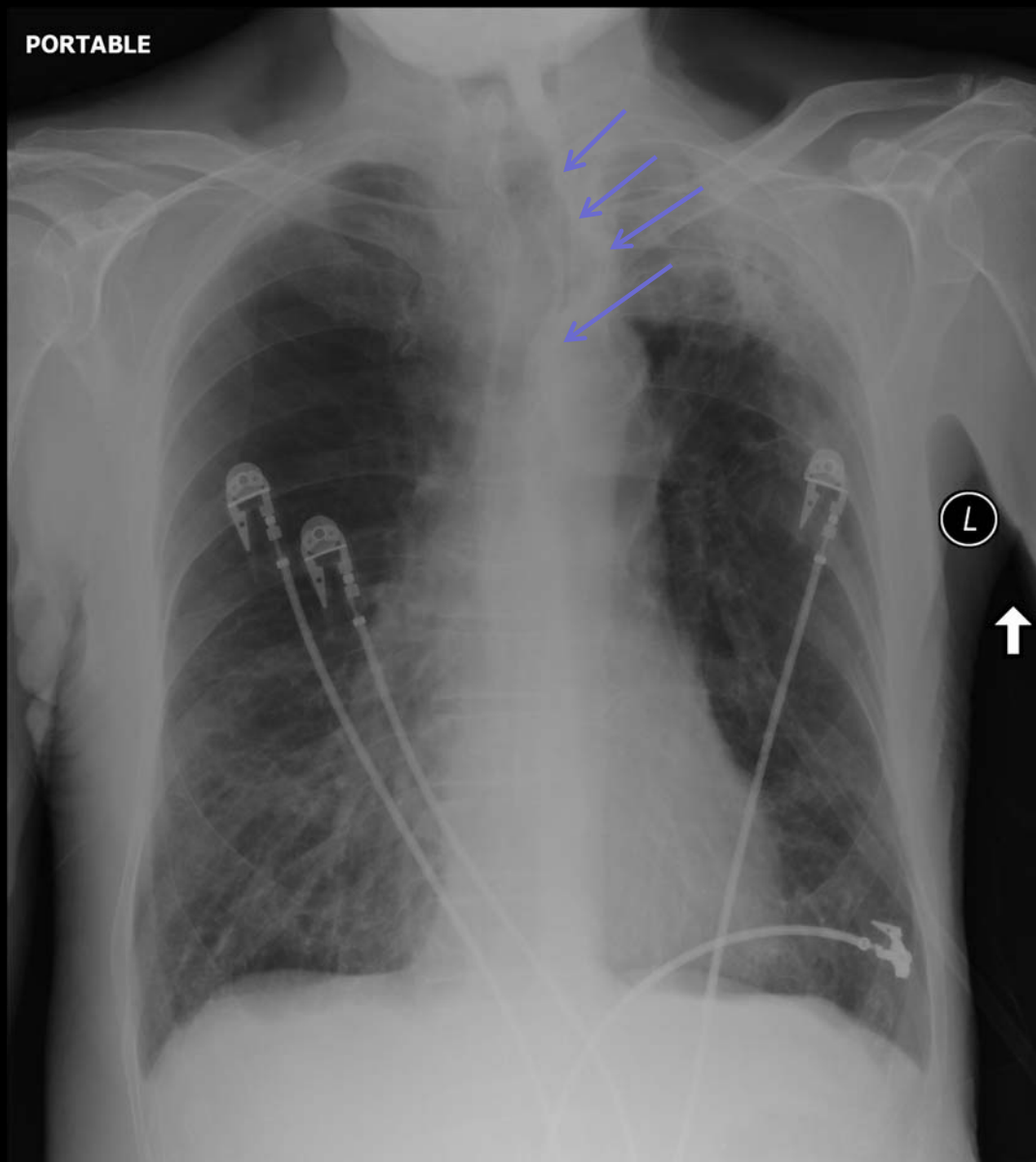


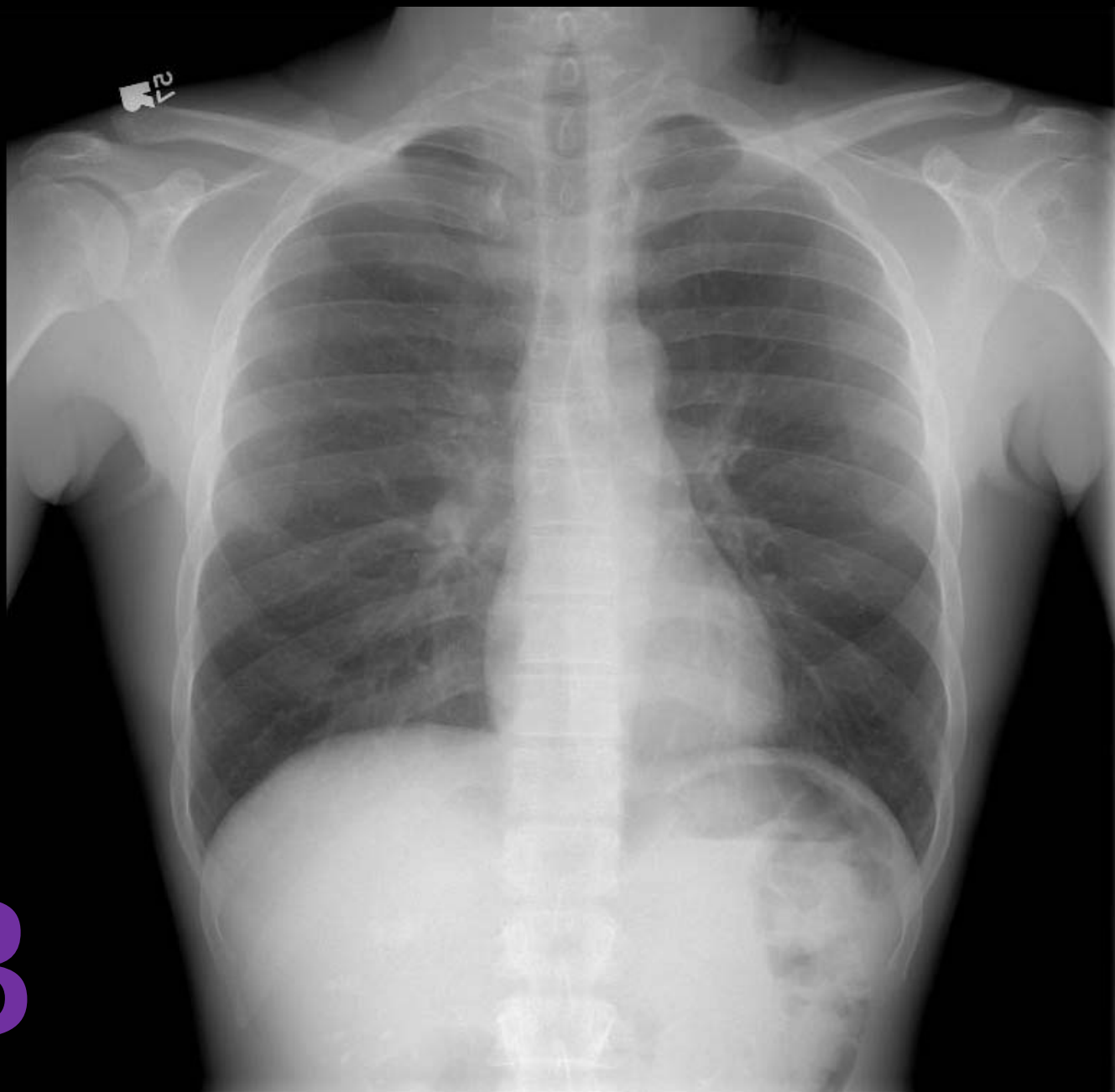
A



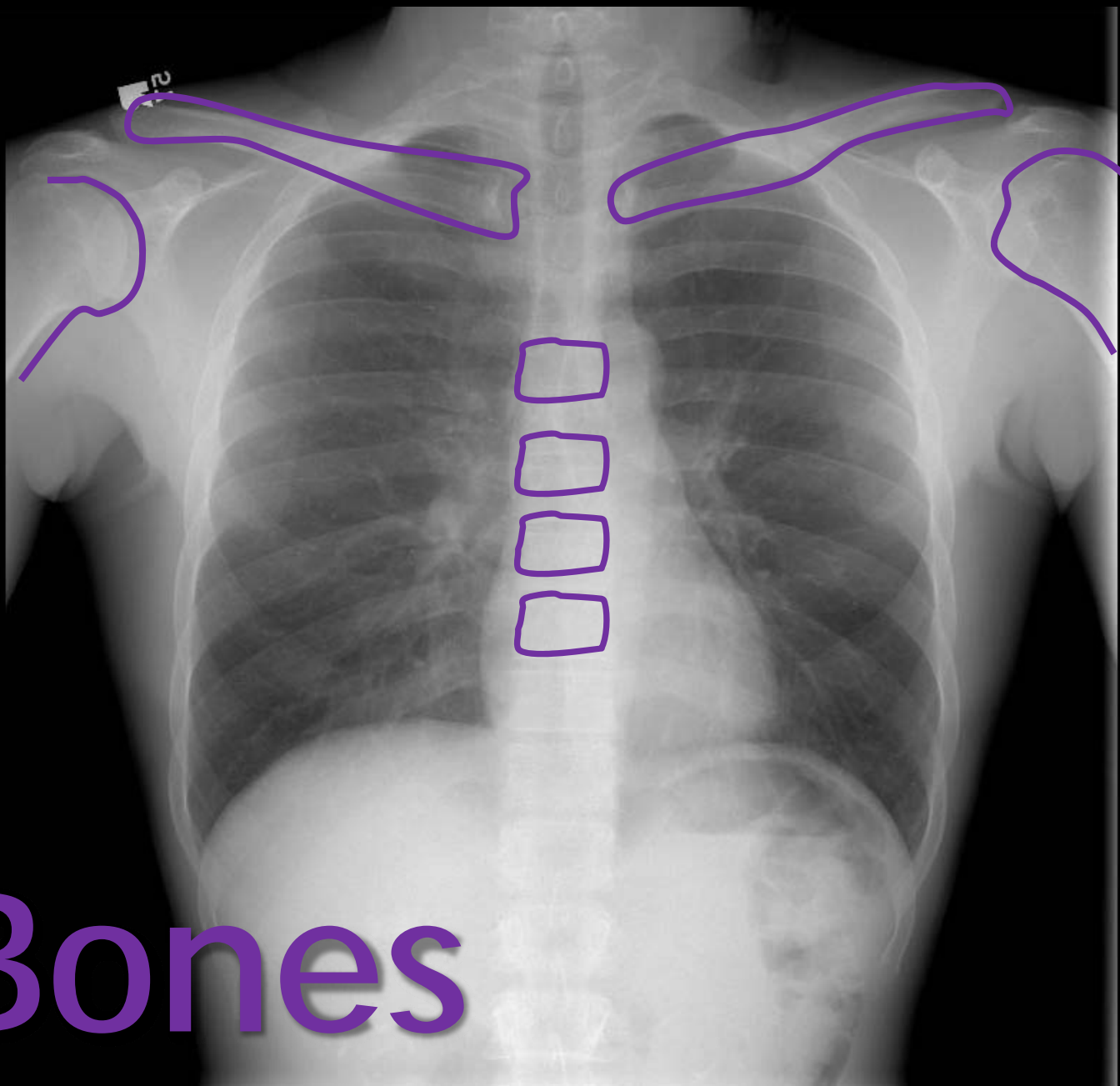
Airway

Tracheal Deviation



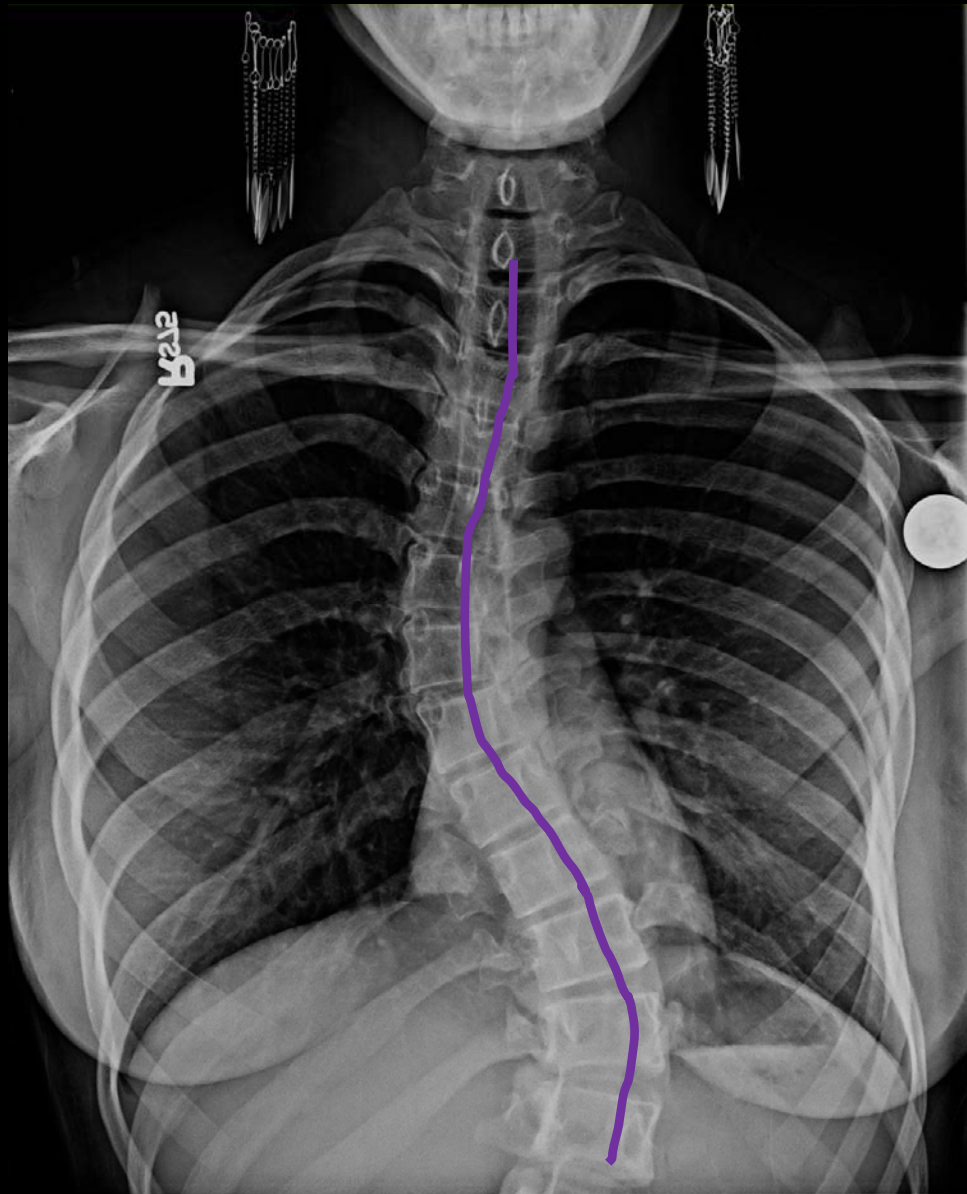


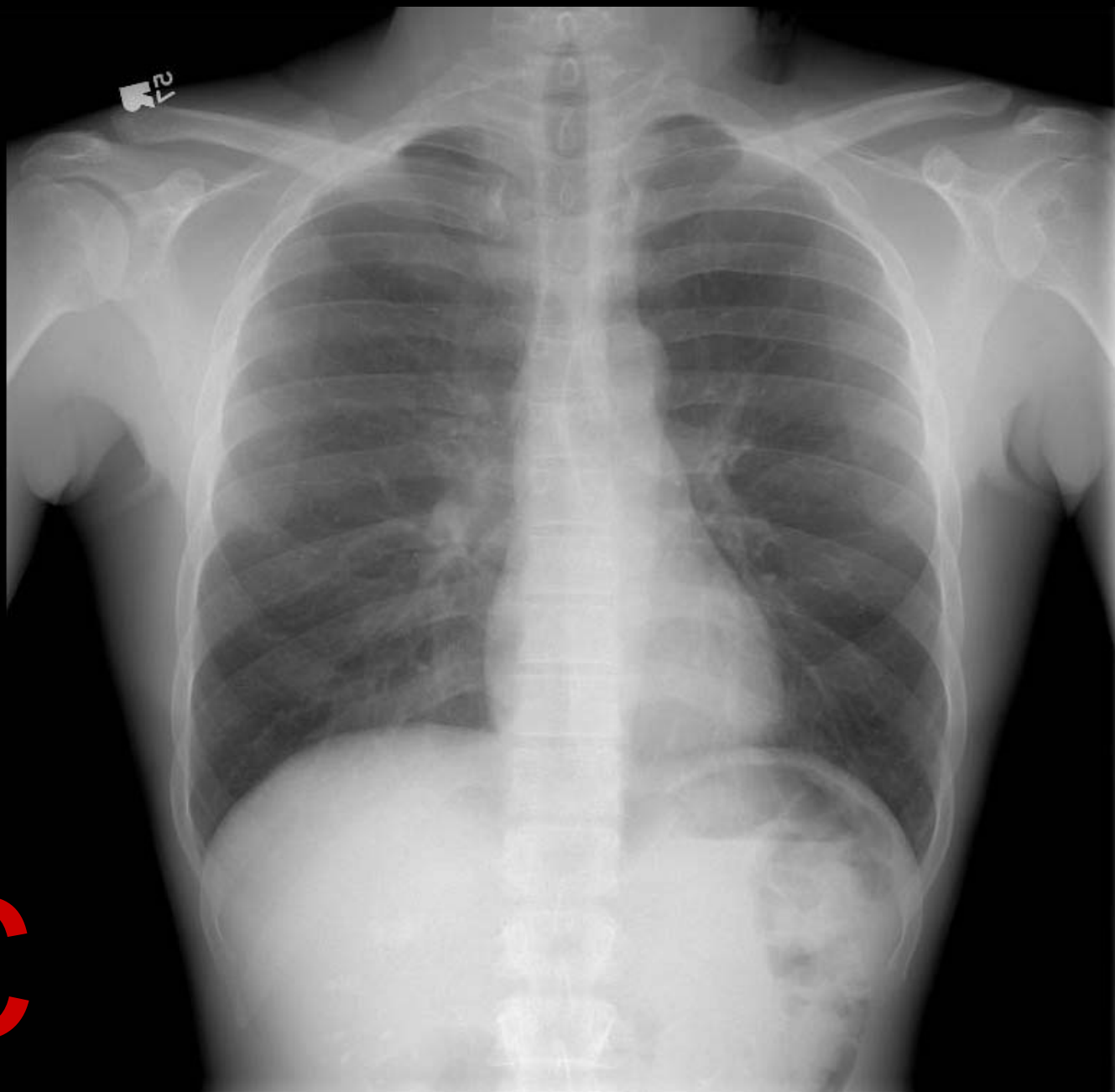
B



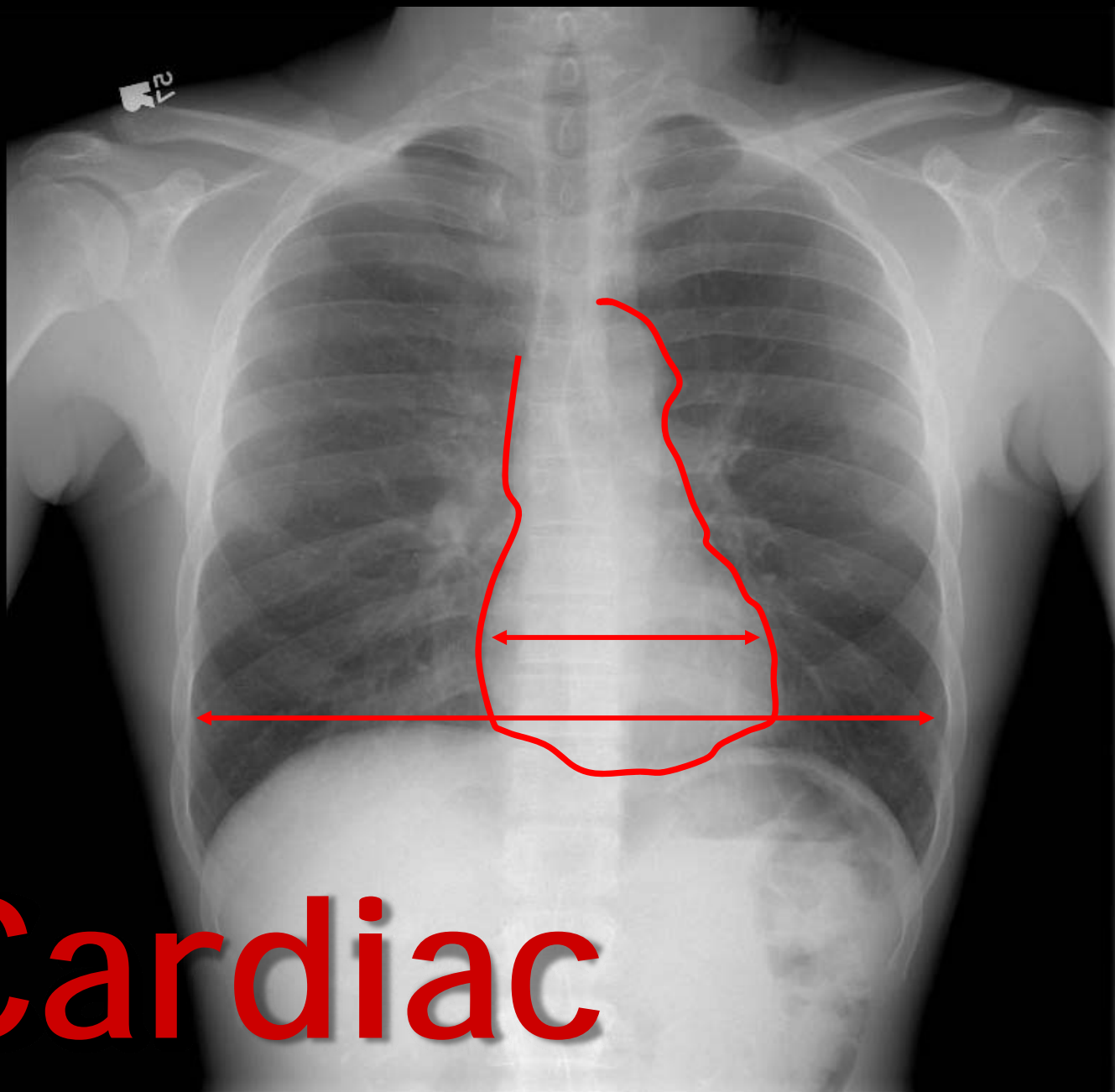
Bones

Thoracic Scoliosis



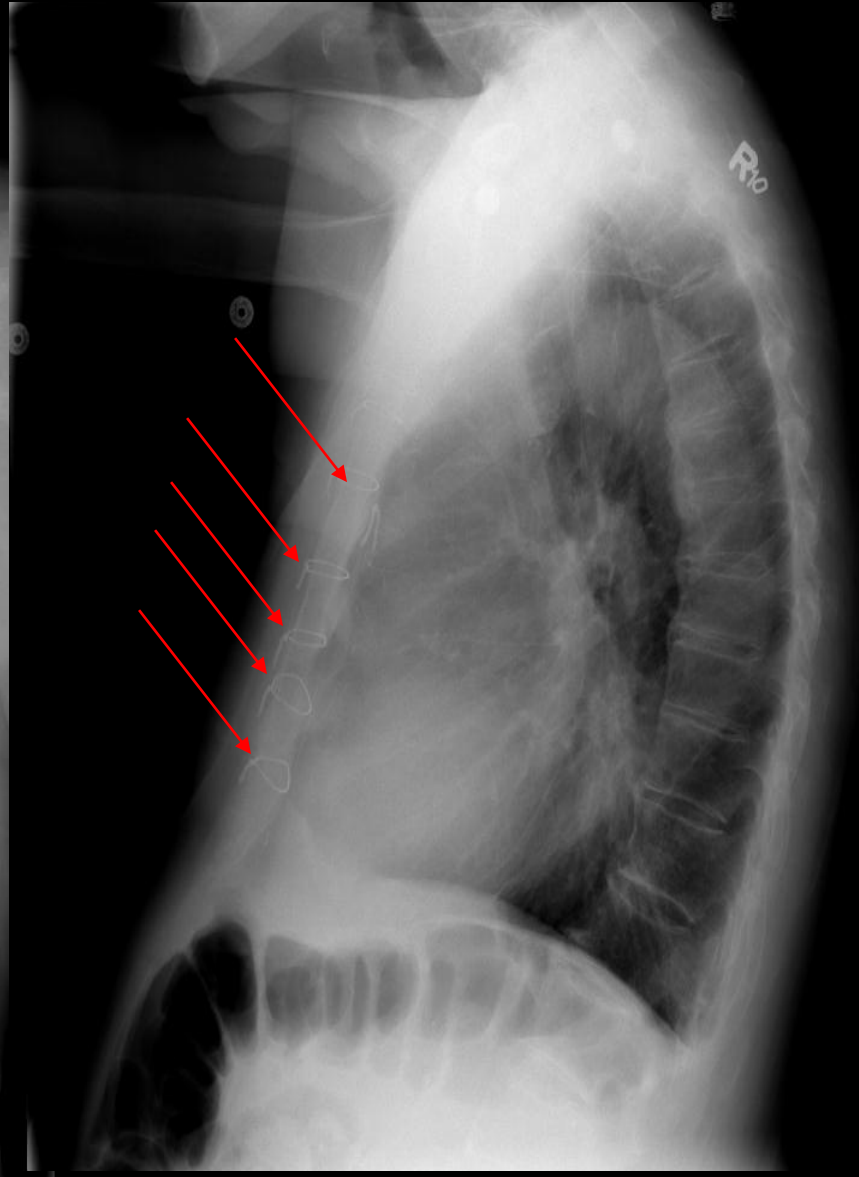
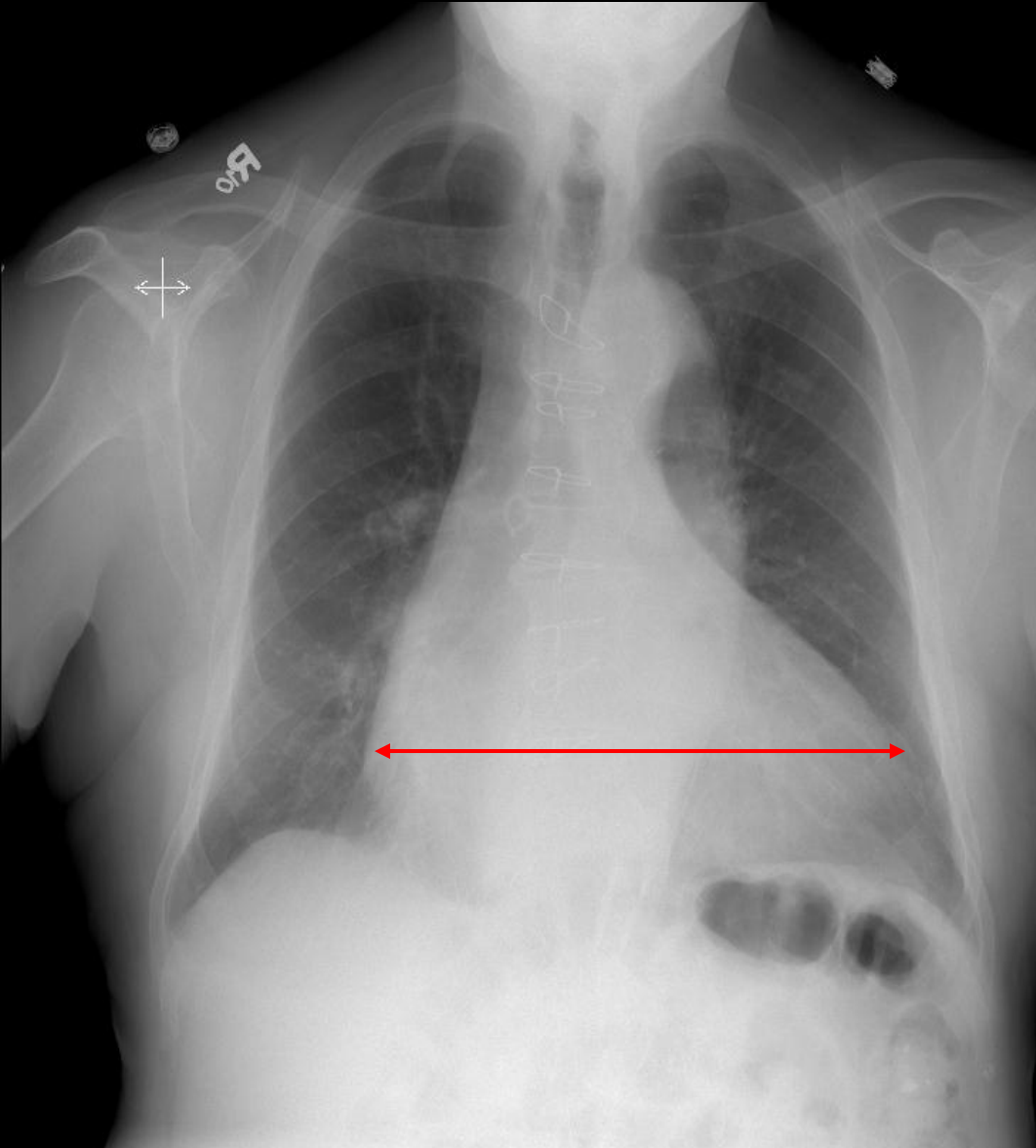


C

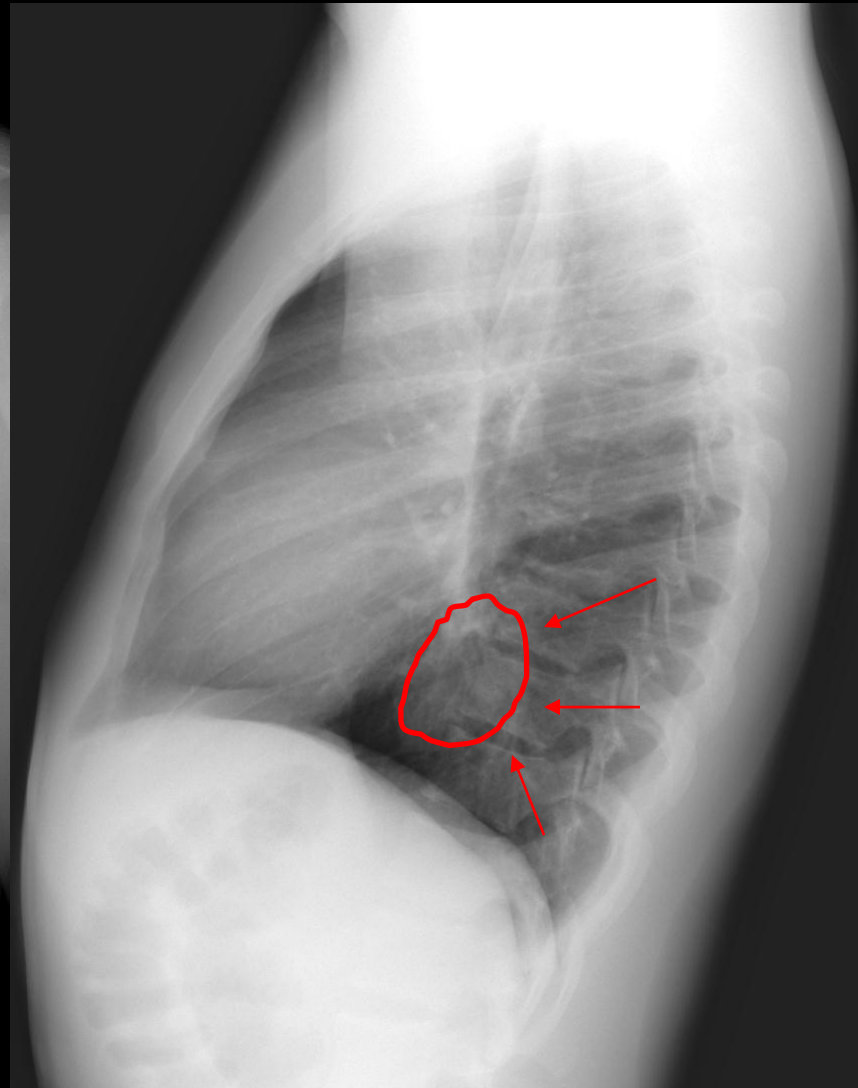
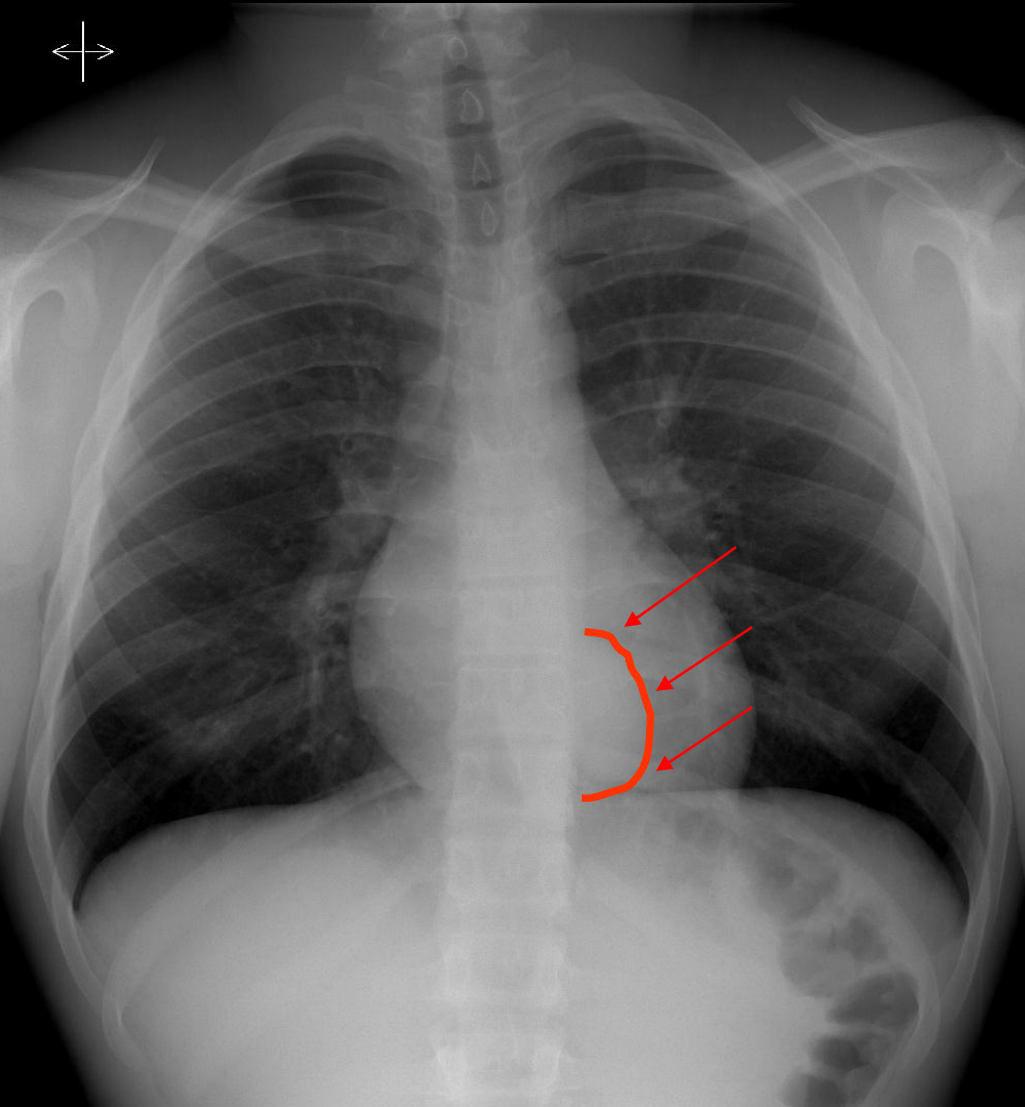


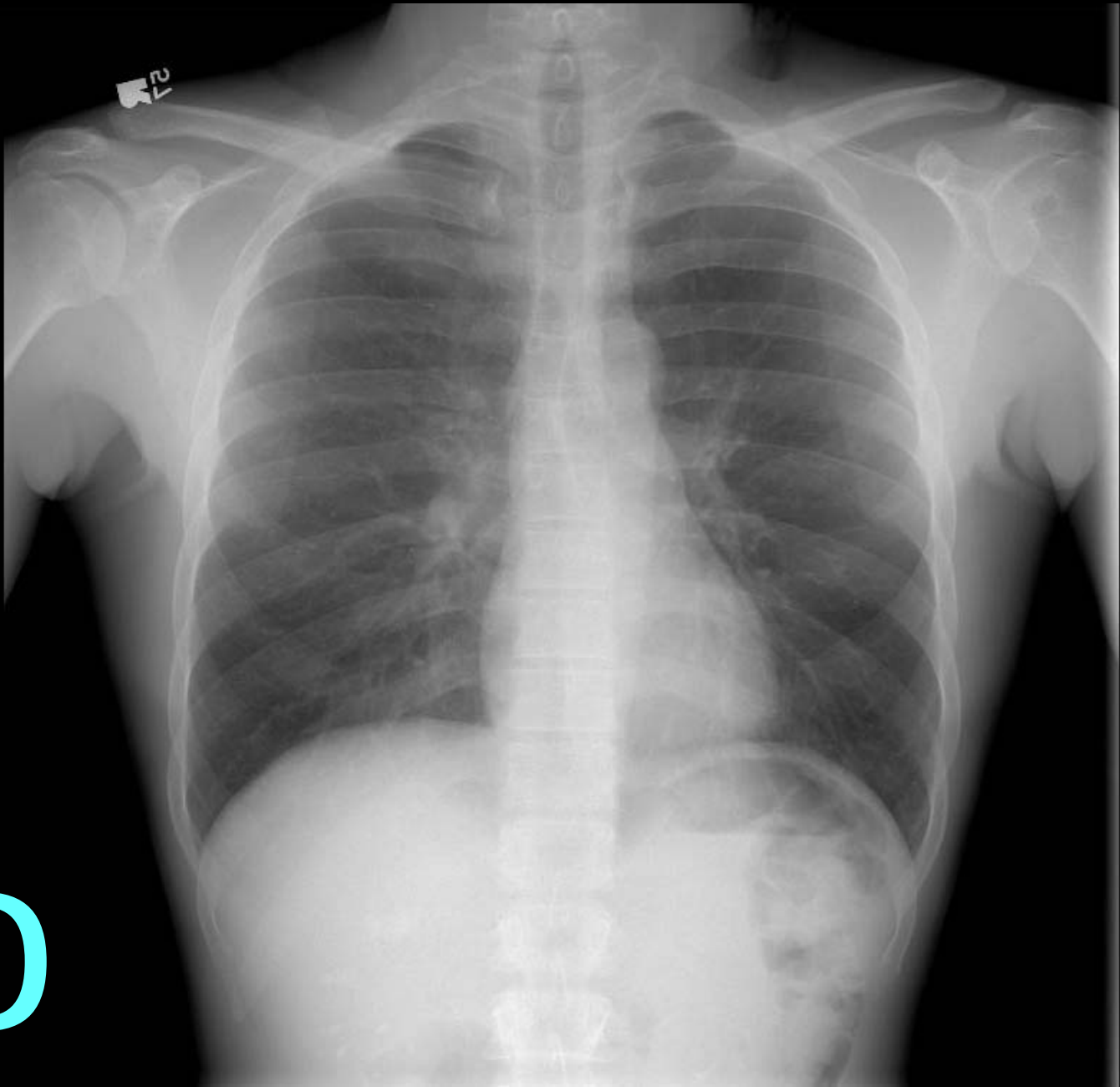
Cardiac

Coronary Artery Bypass Graft Surgery (CABG)

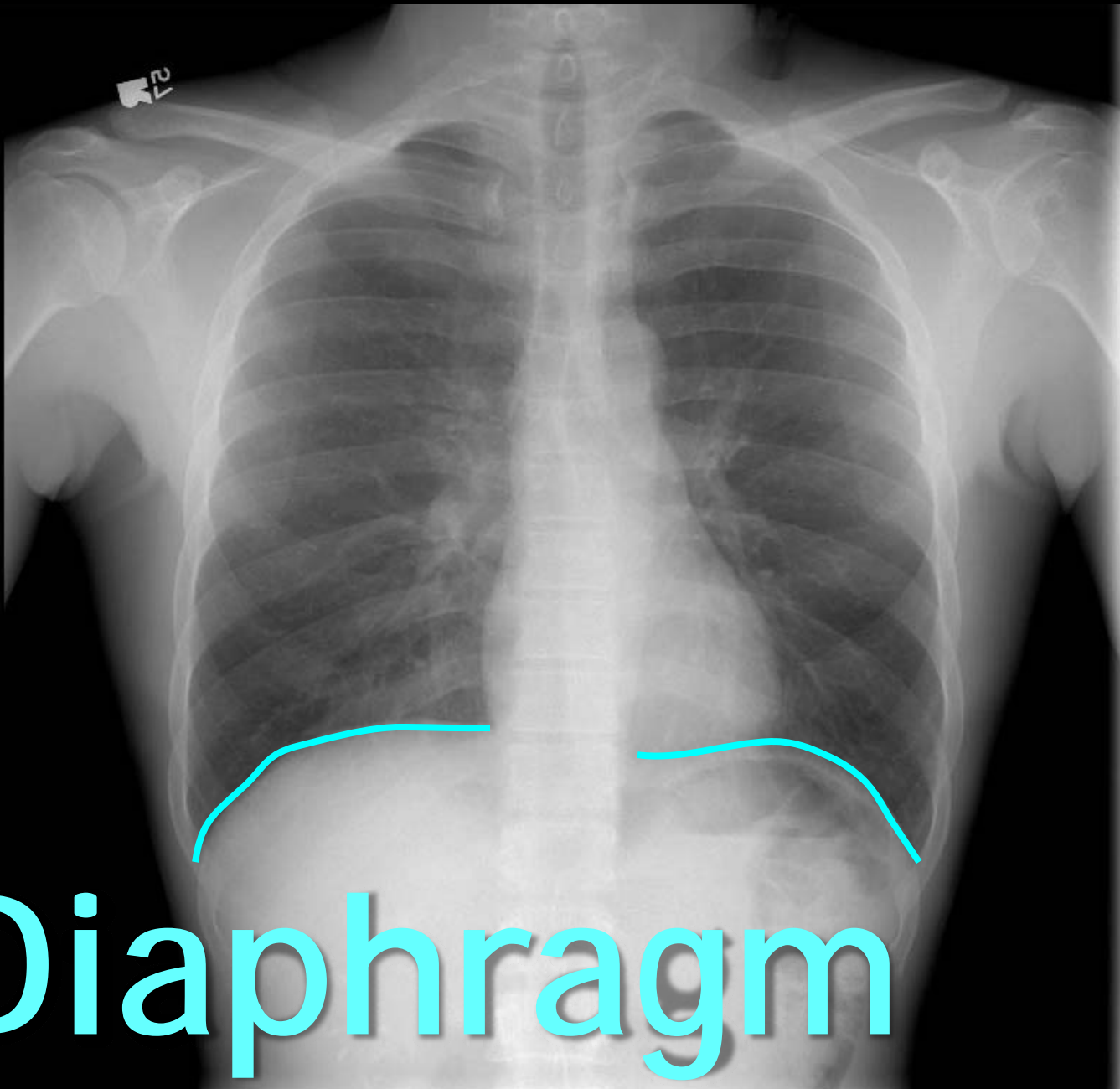


Retrocardiac Mass- Ganglioneuroma



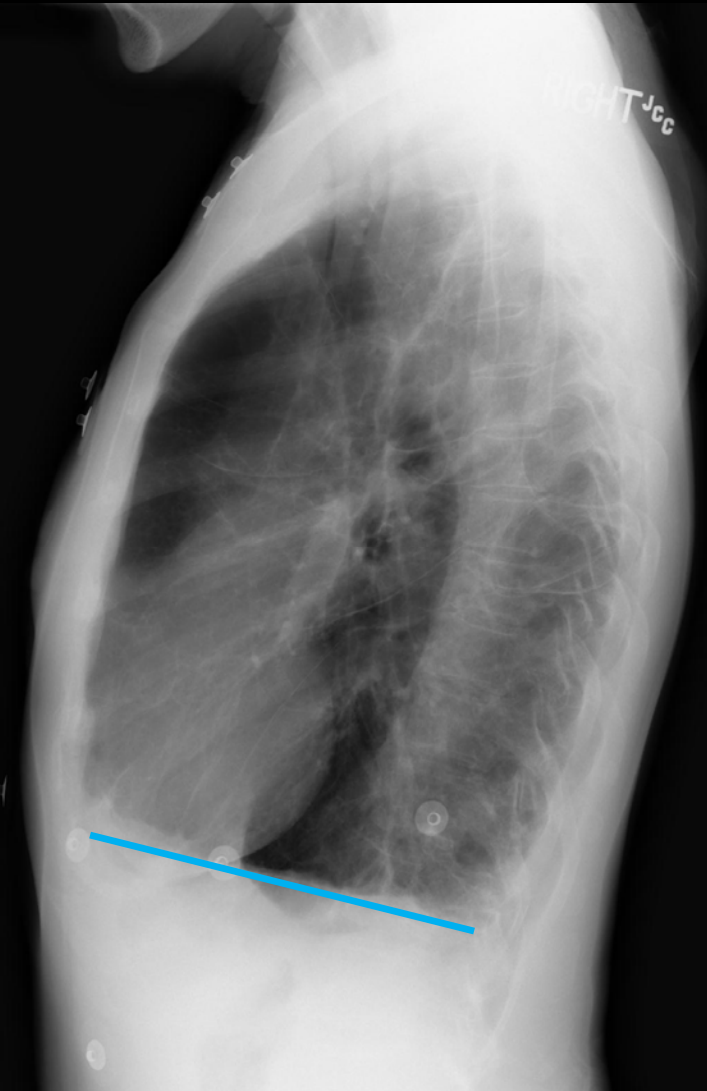
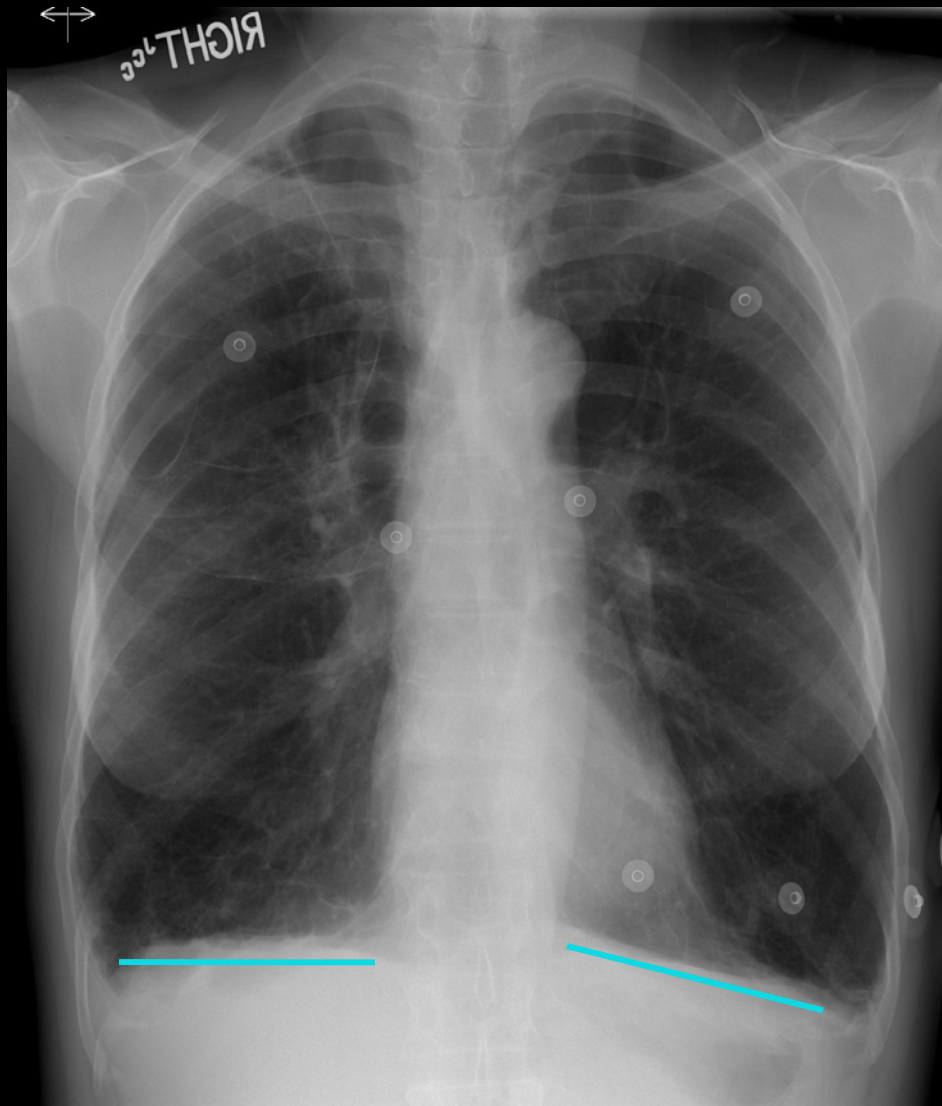


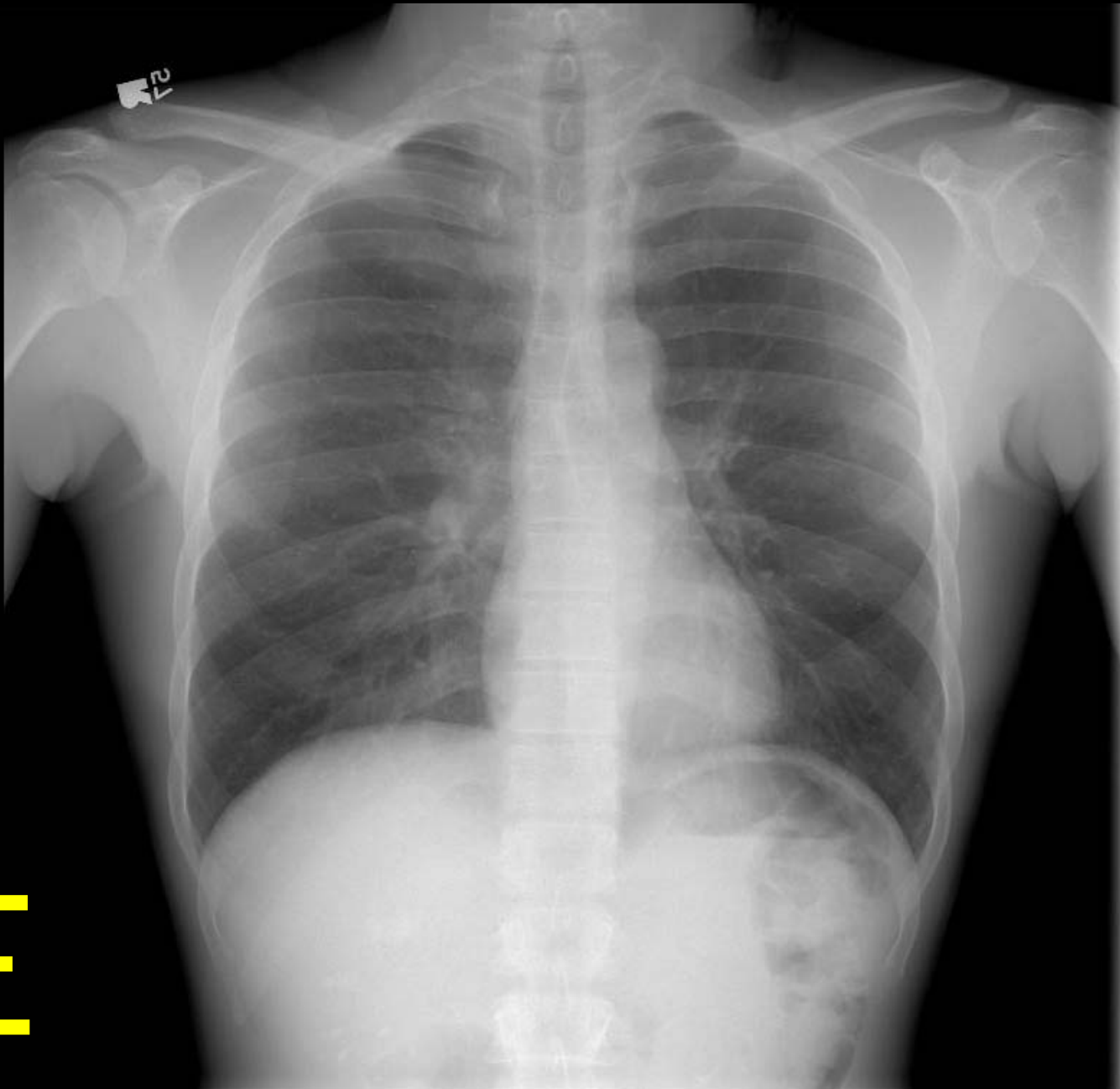
D



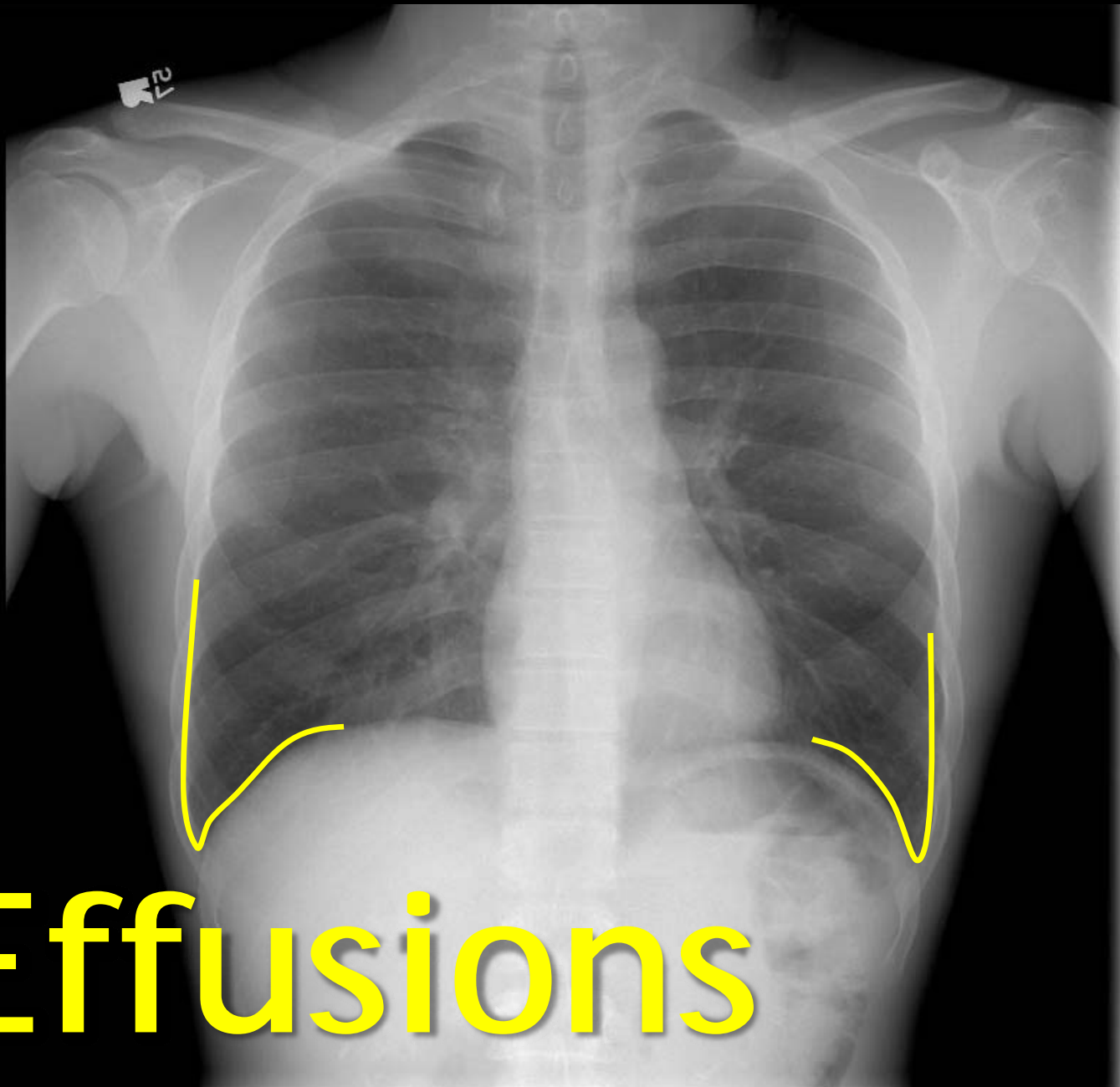
Diaphragm

Chronic Obstructive Pulmonary Disease (COPD)



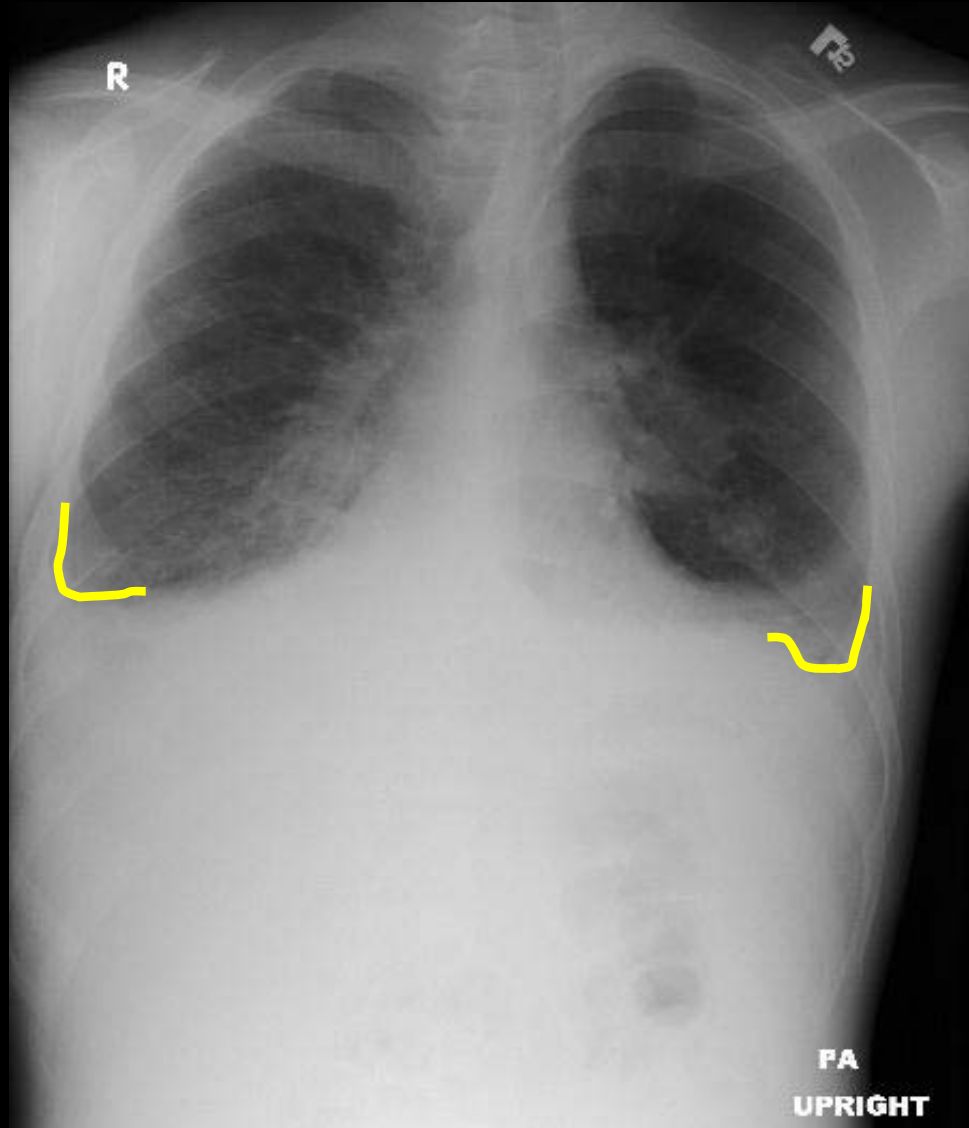


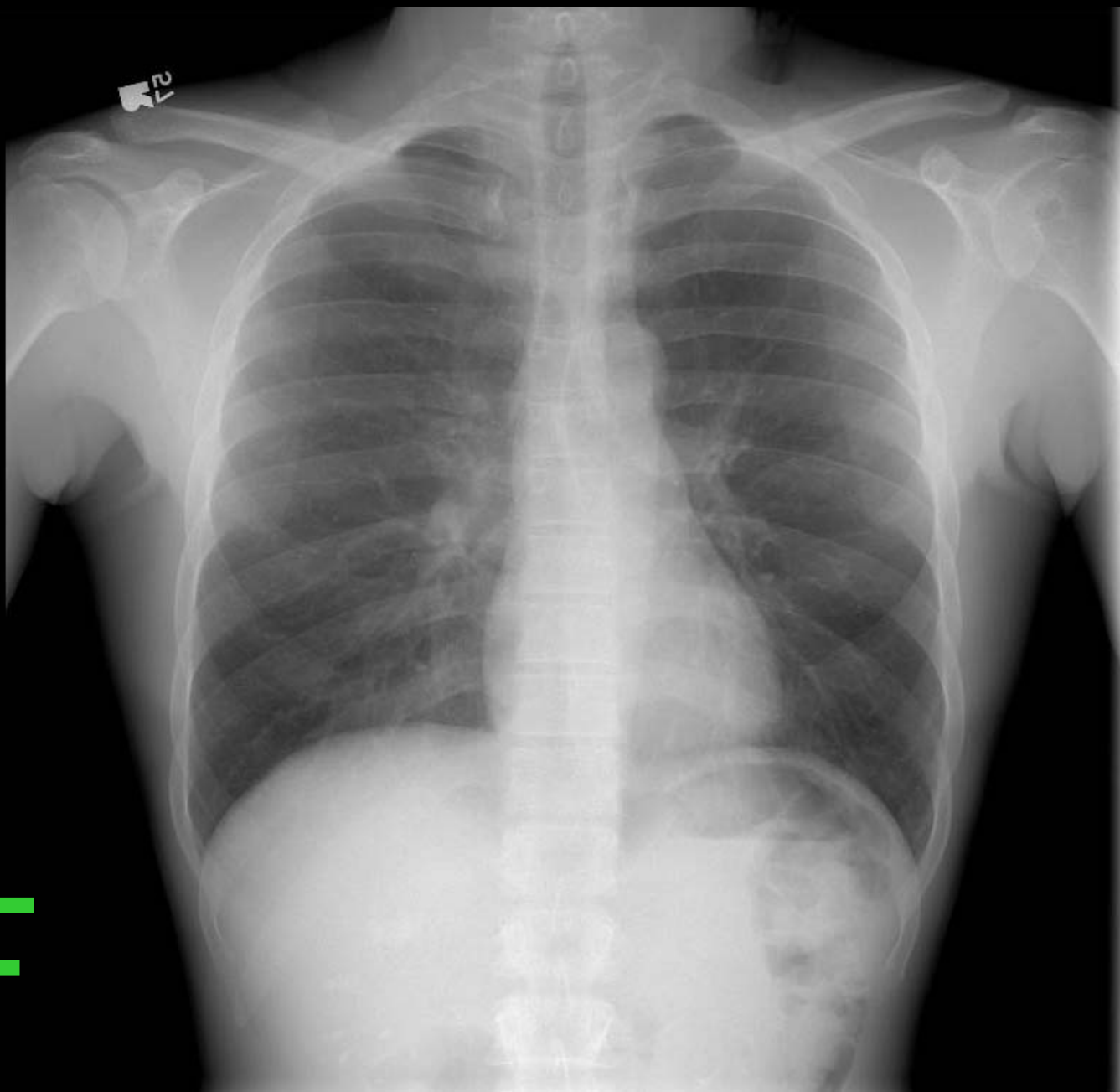
E



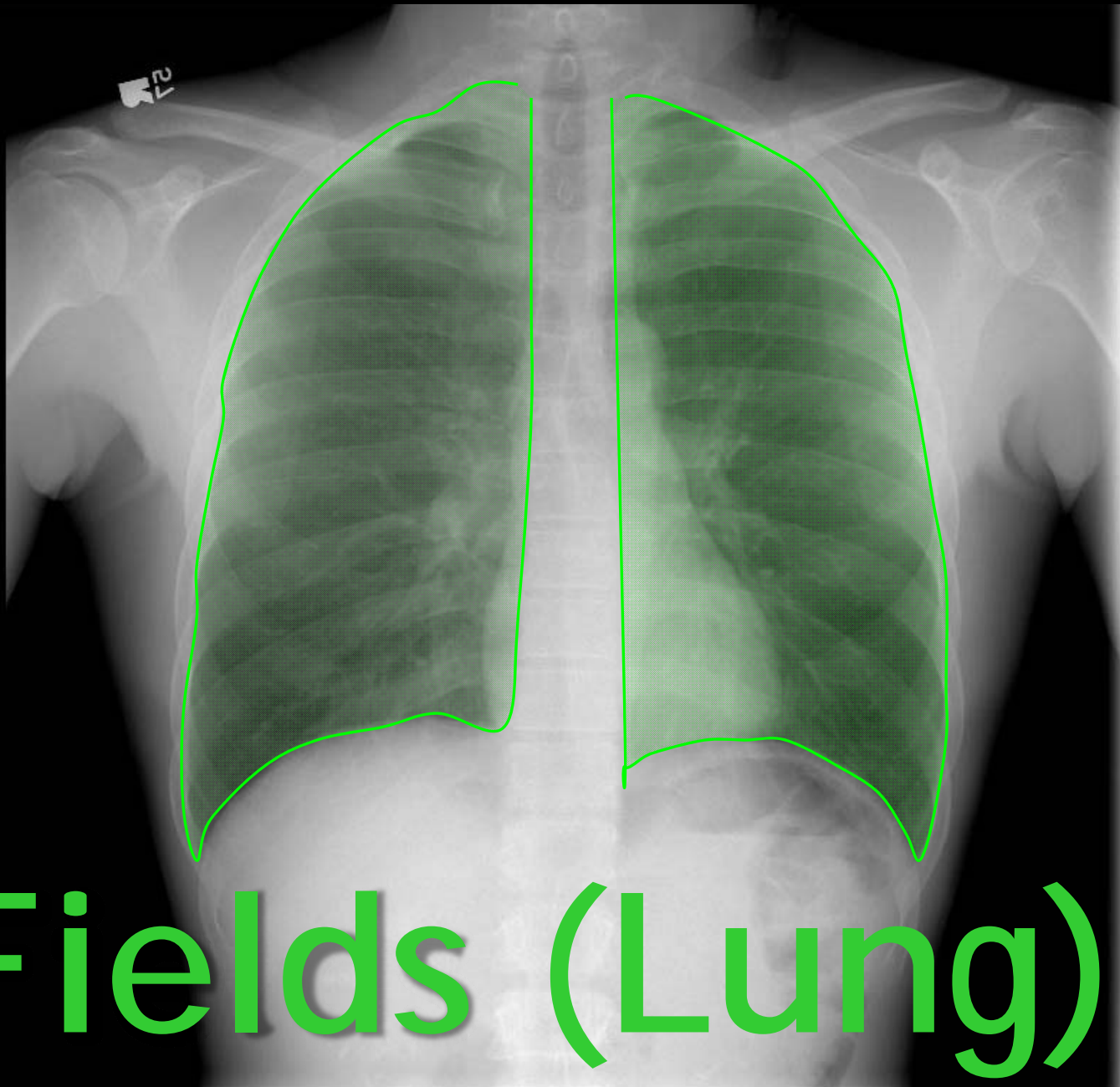
Effusions

Bilateral Pleural Effusions



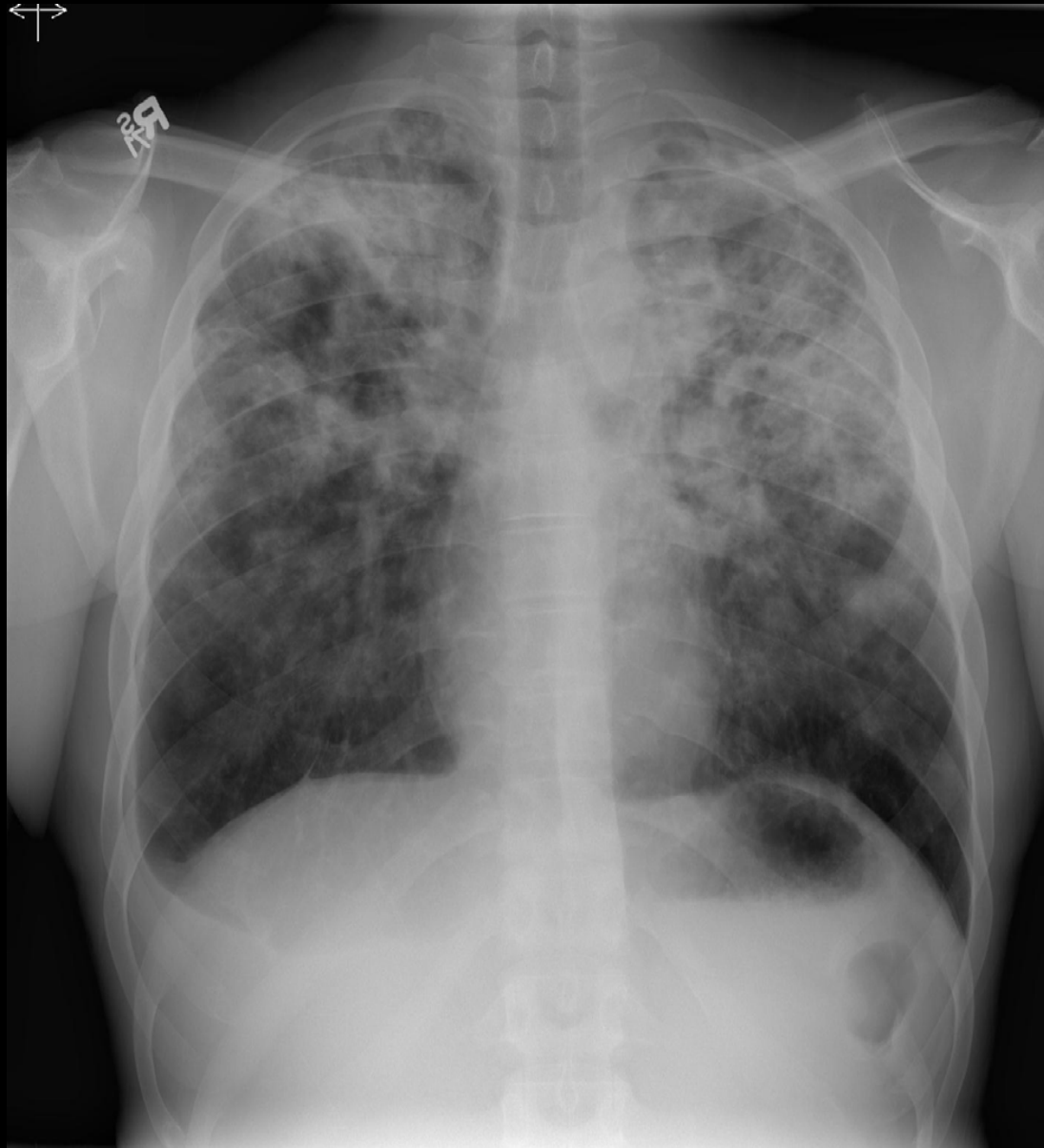


F

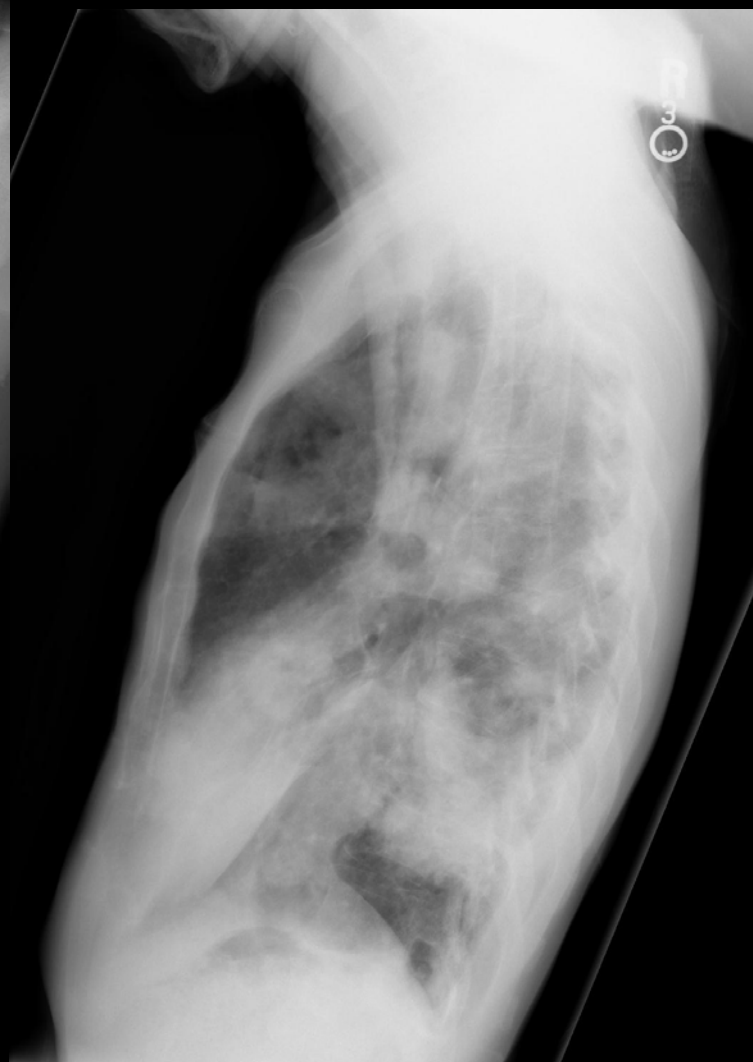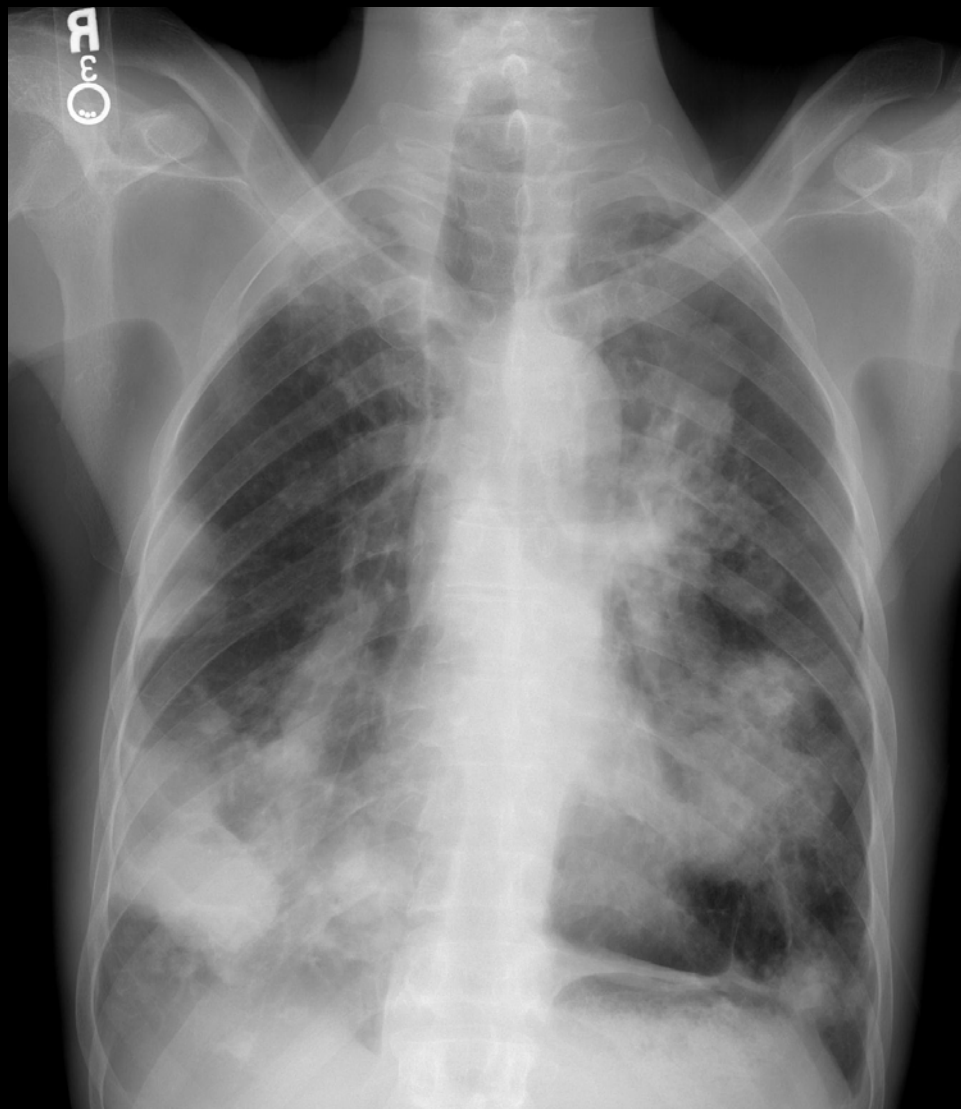


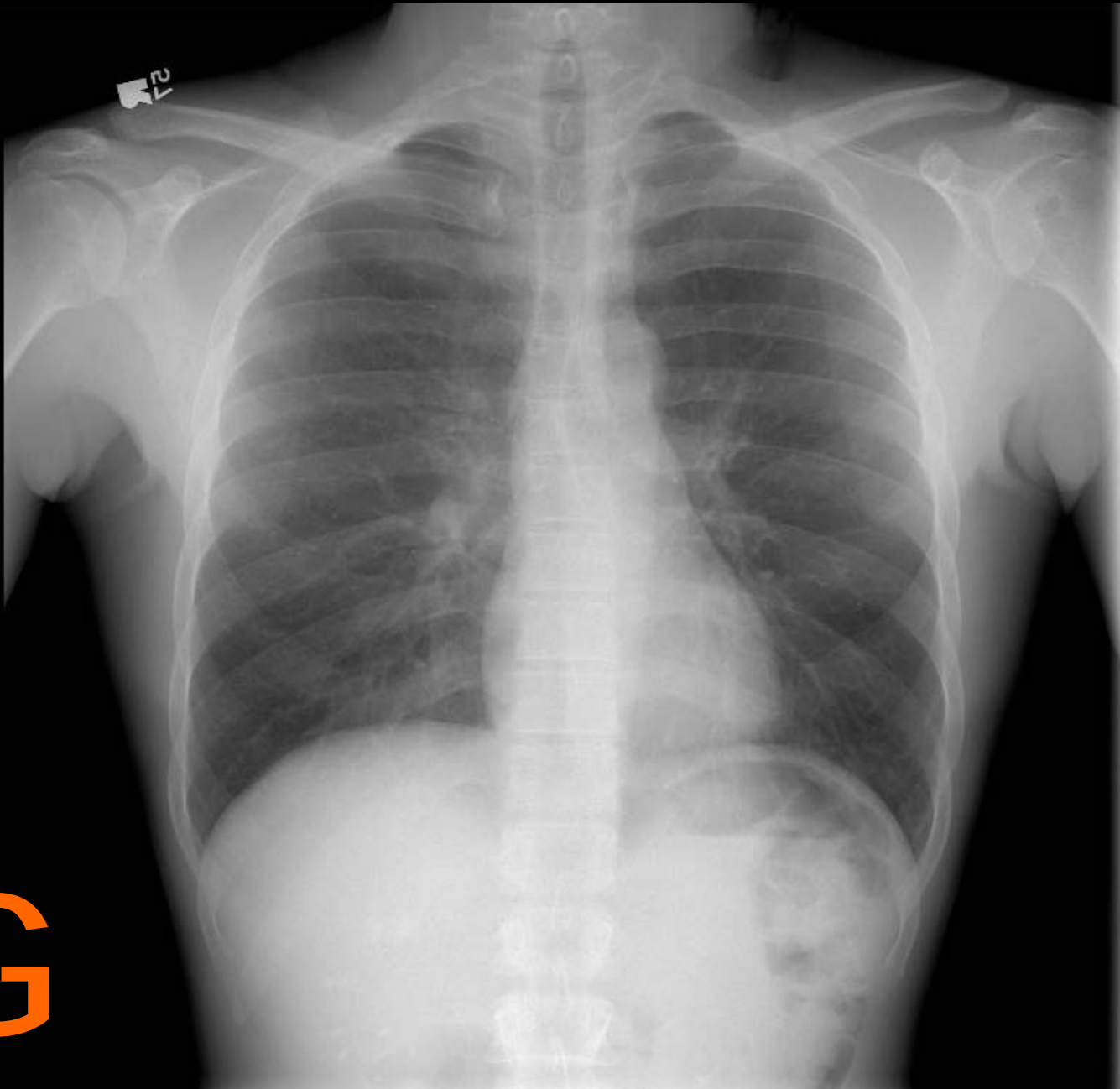
Fields (Lung)

Bilateral Upper Lobes-Tuberculosis

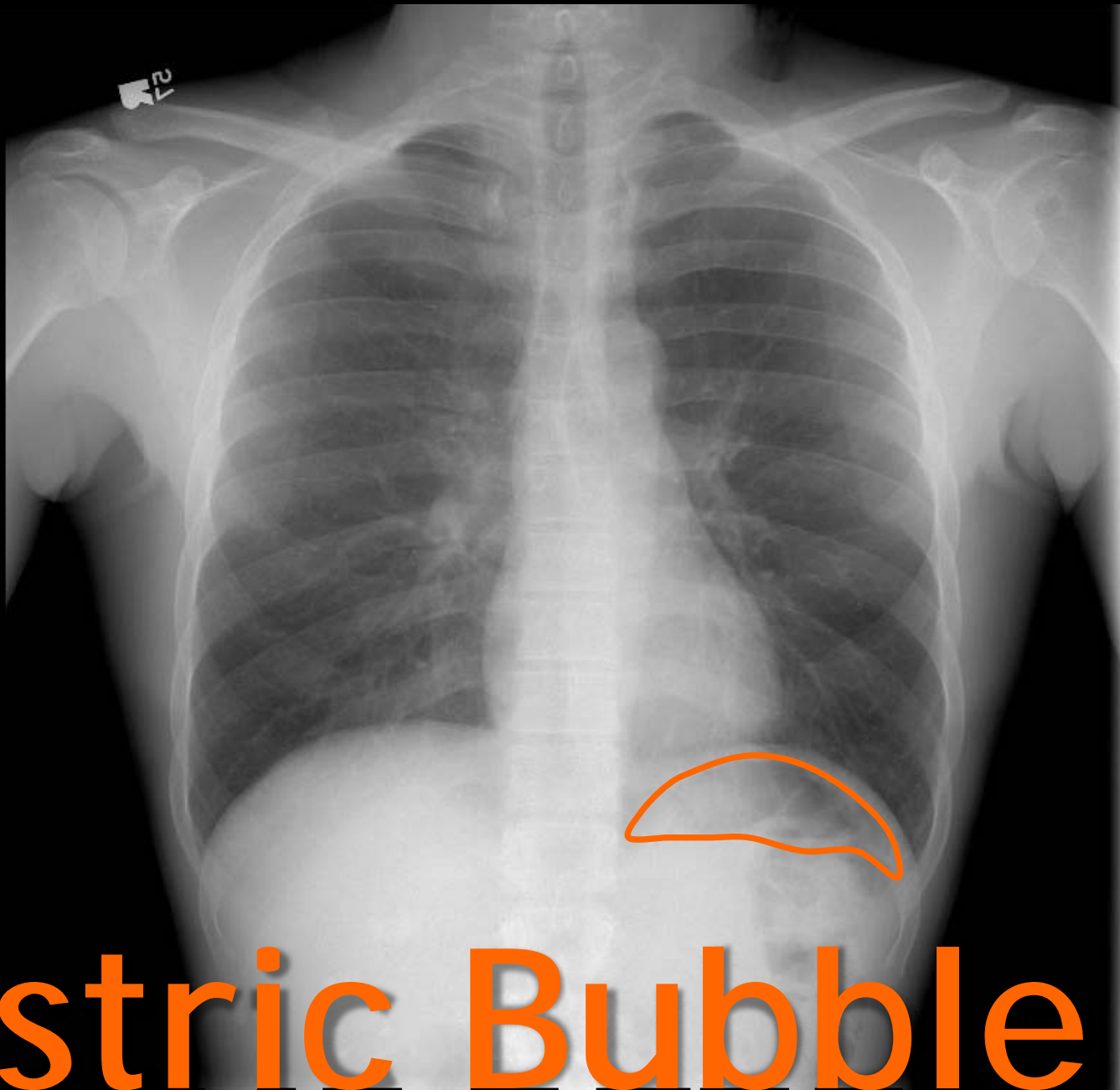


Metastatic Disease- Rectal Ca



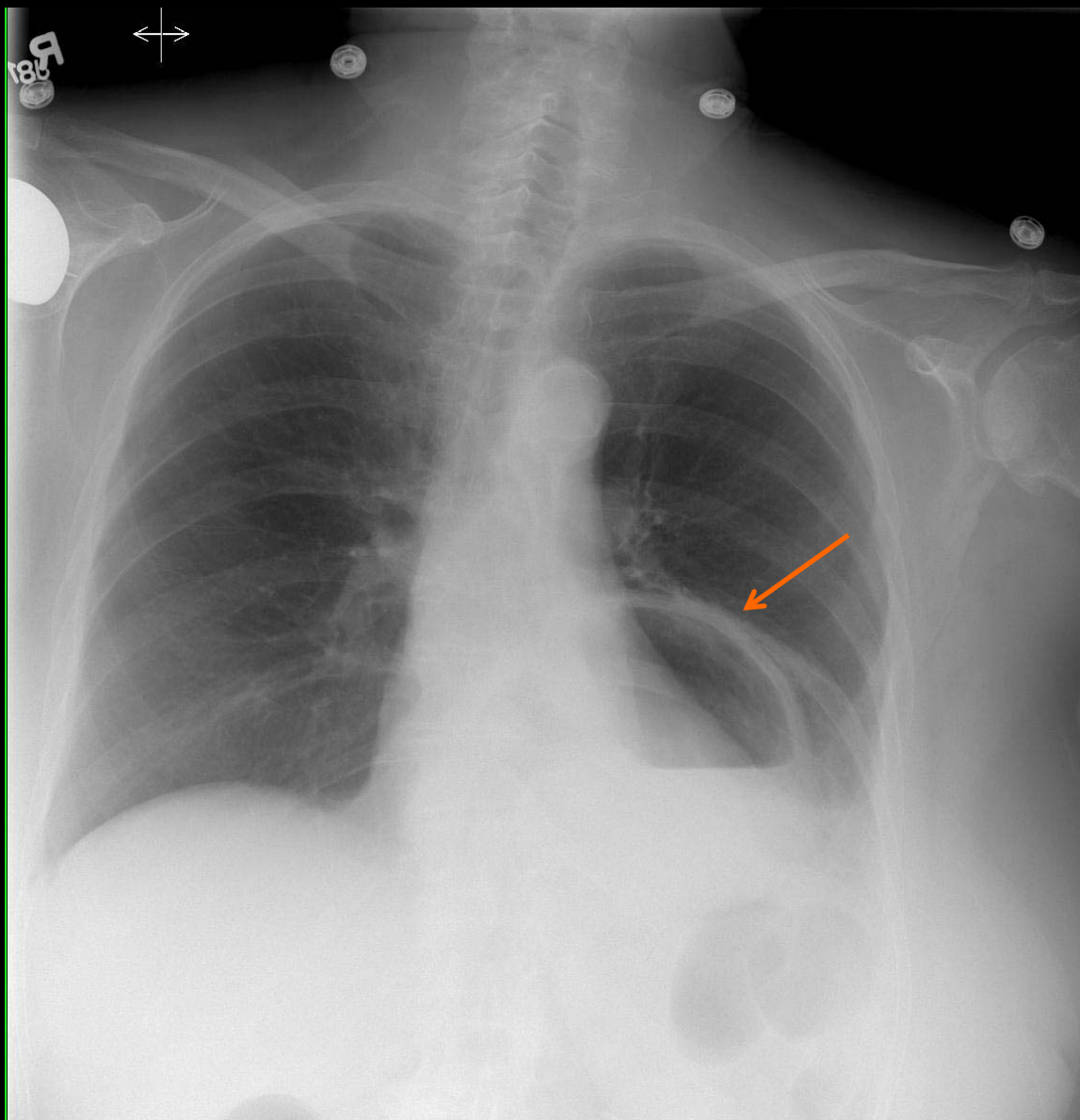


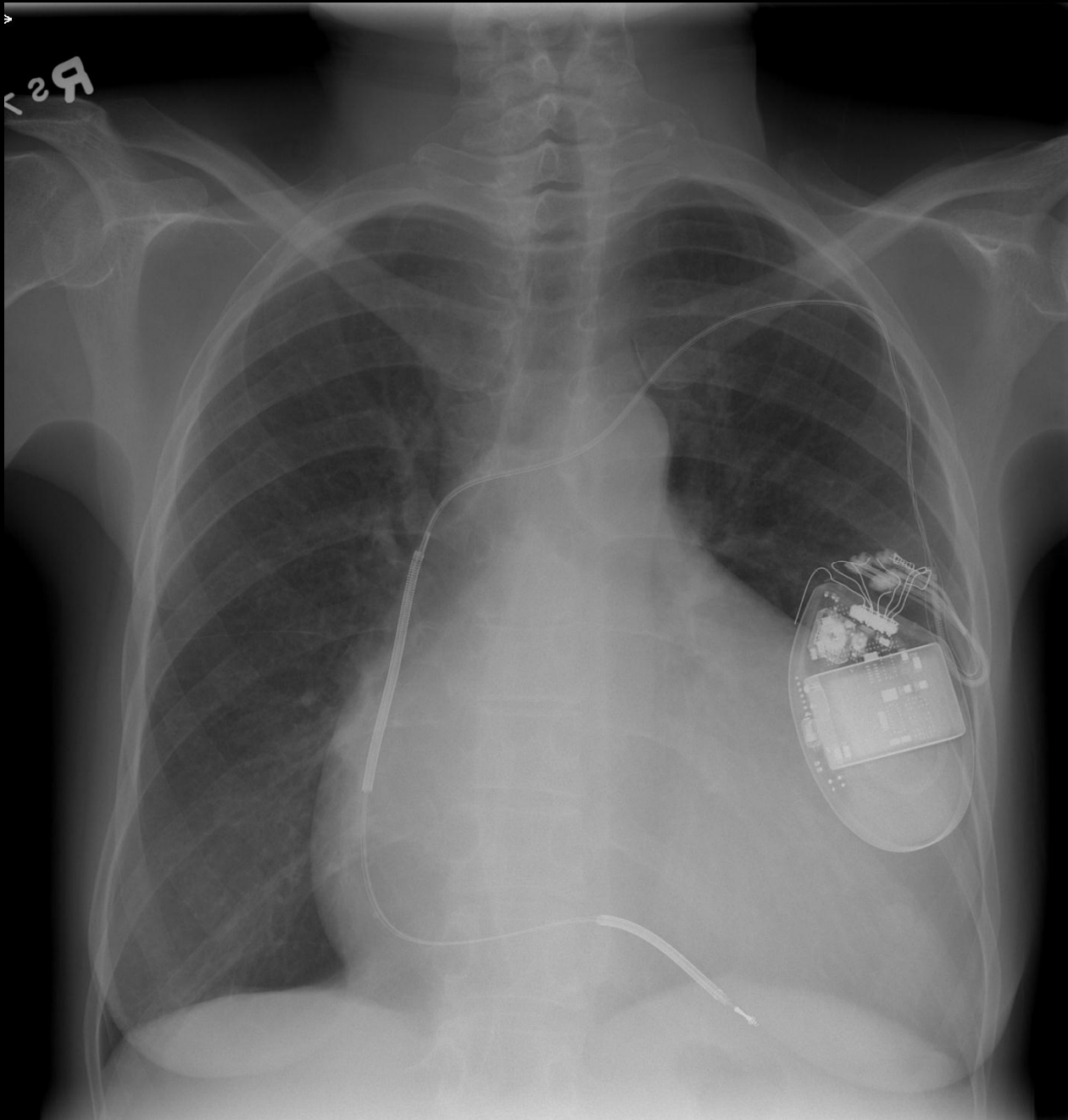
G



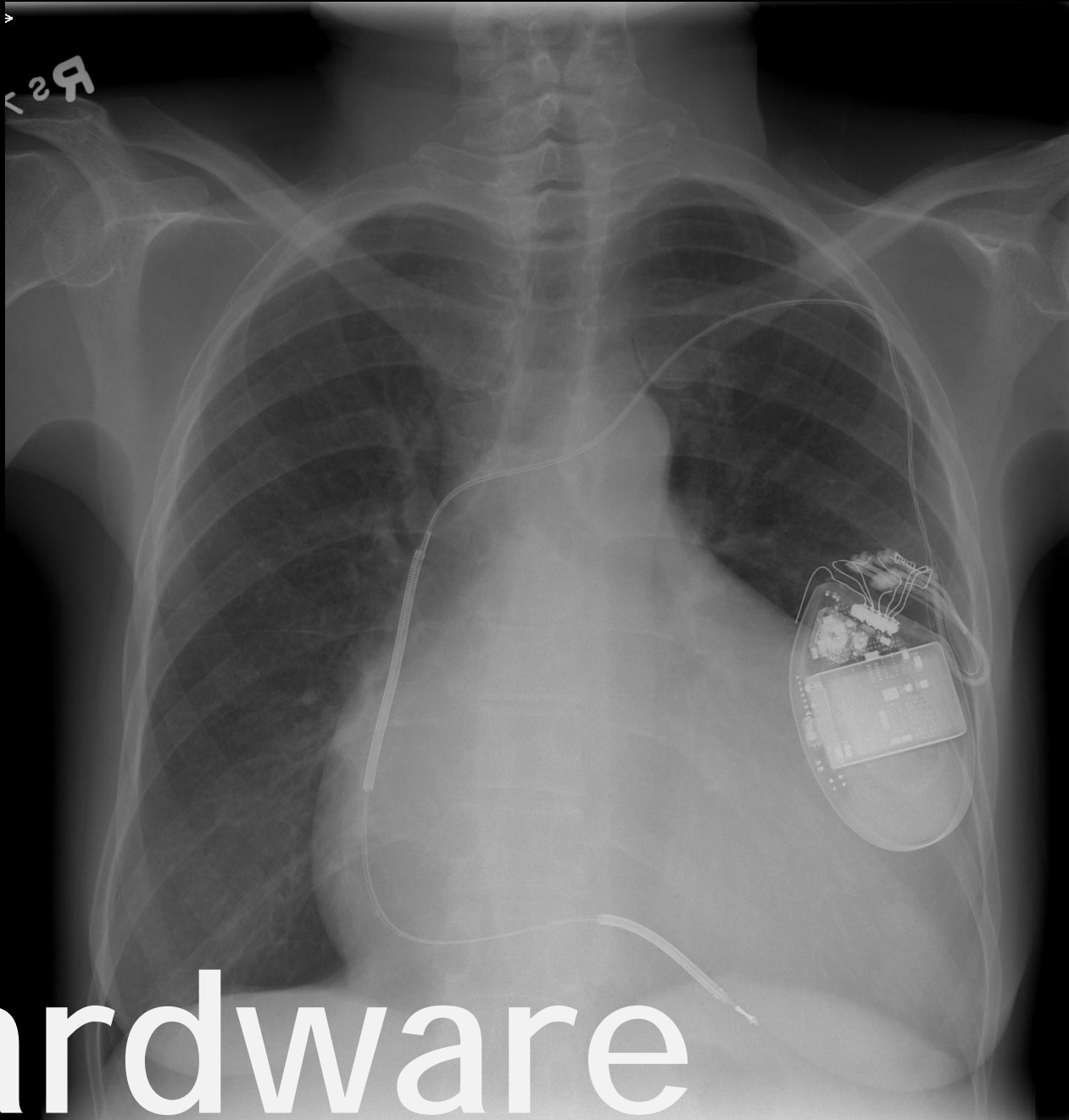
Gastric Bubble

Hiatal Hernia



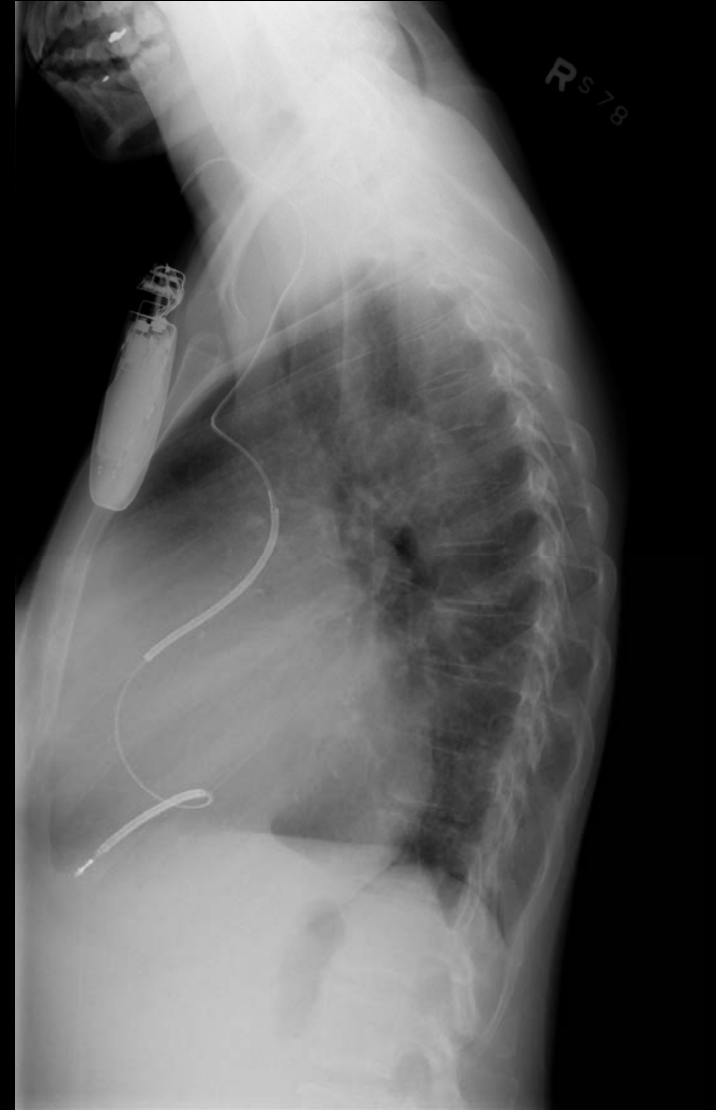
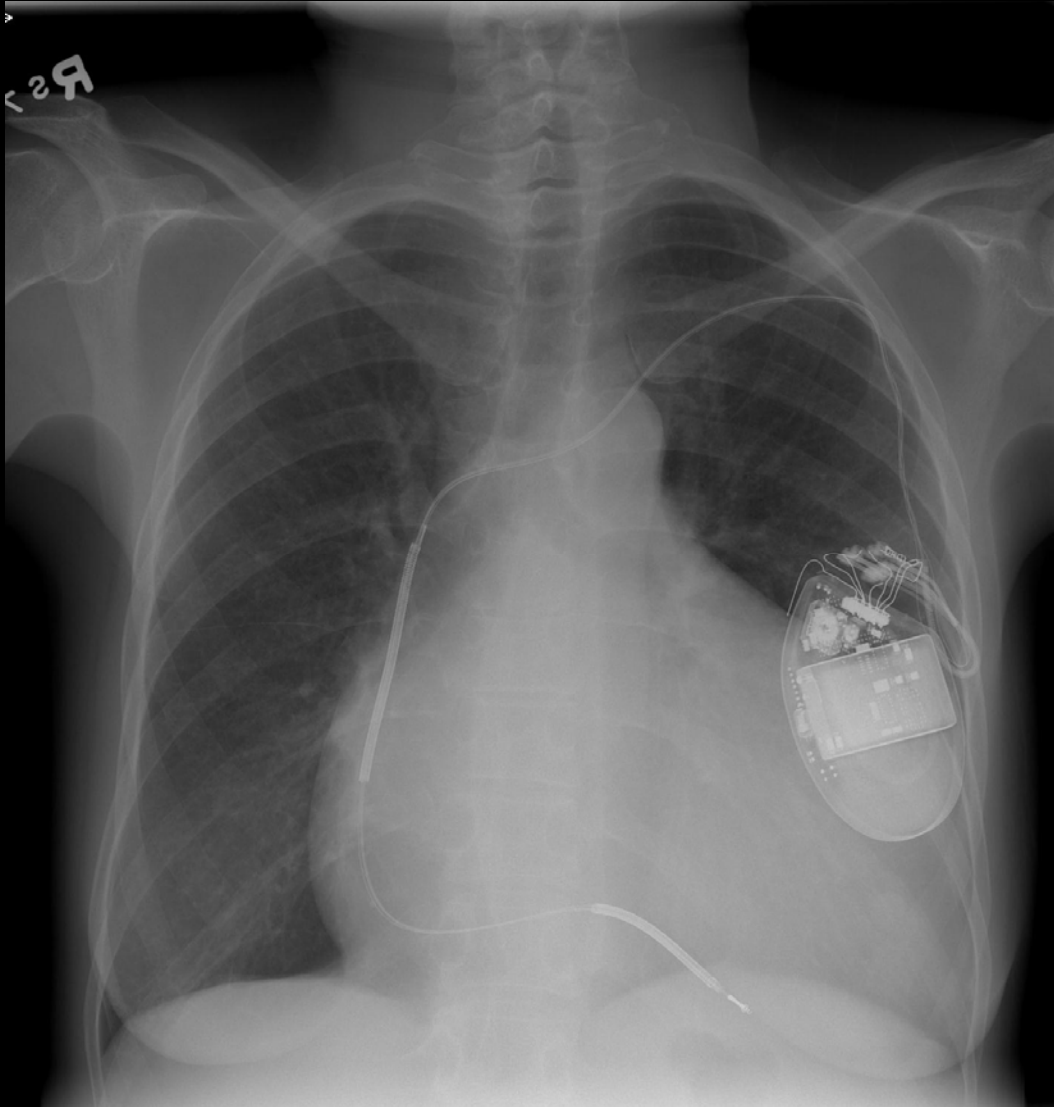


H

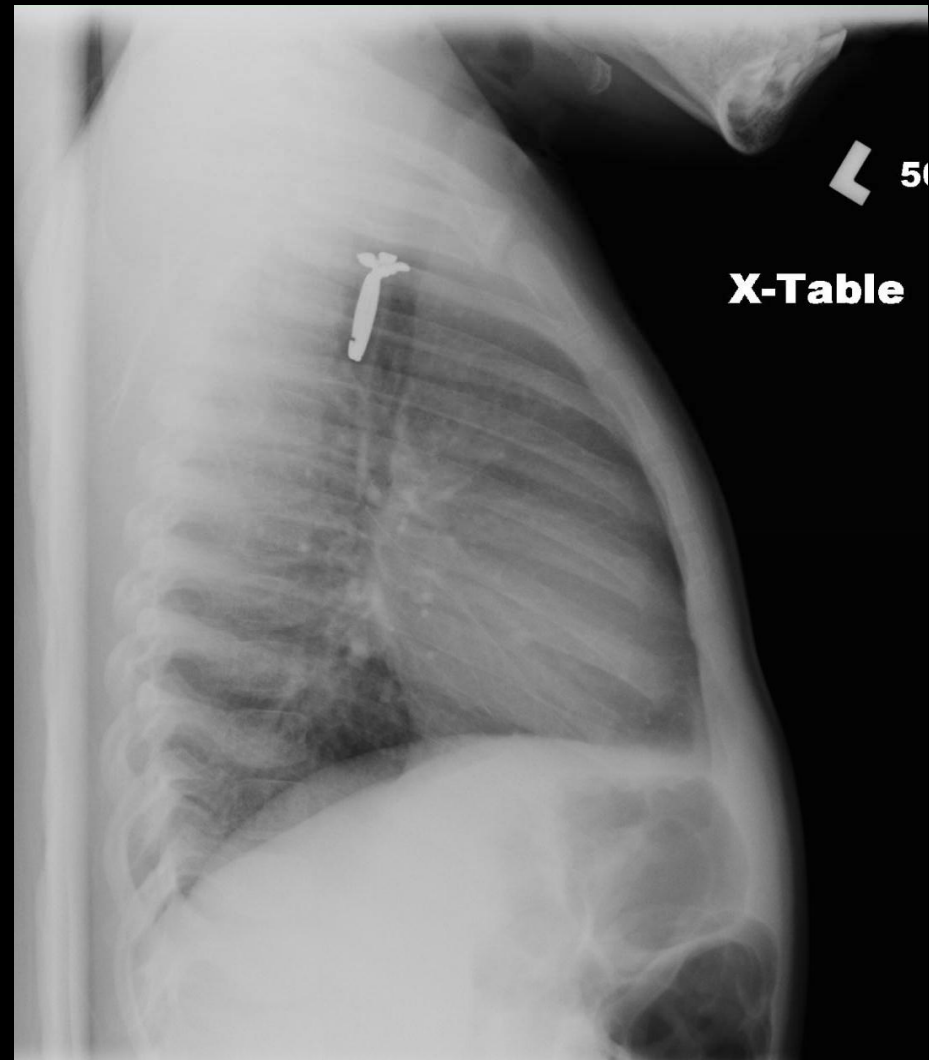
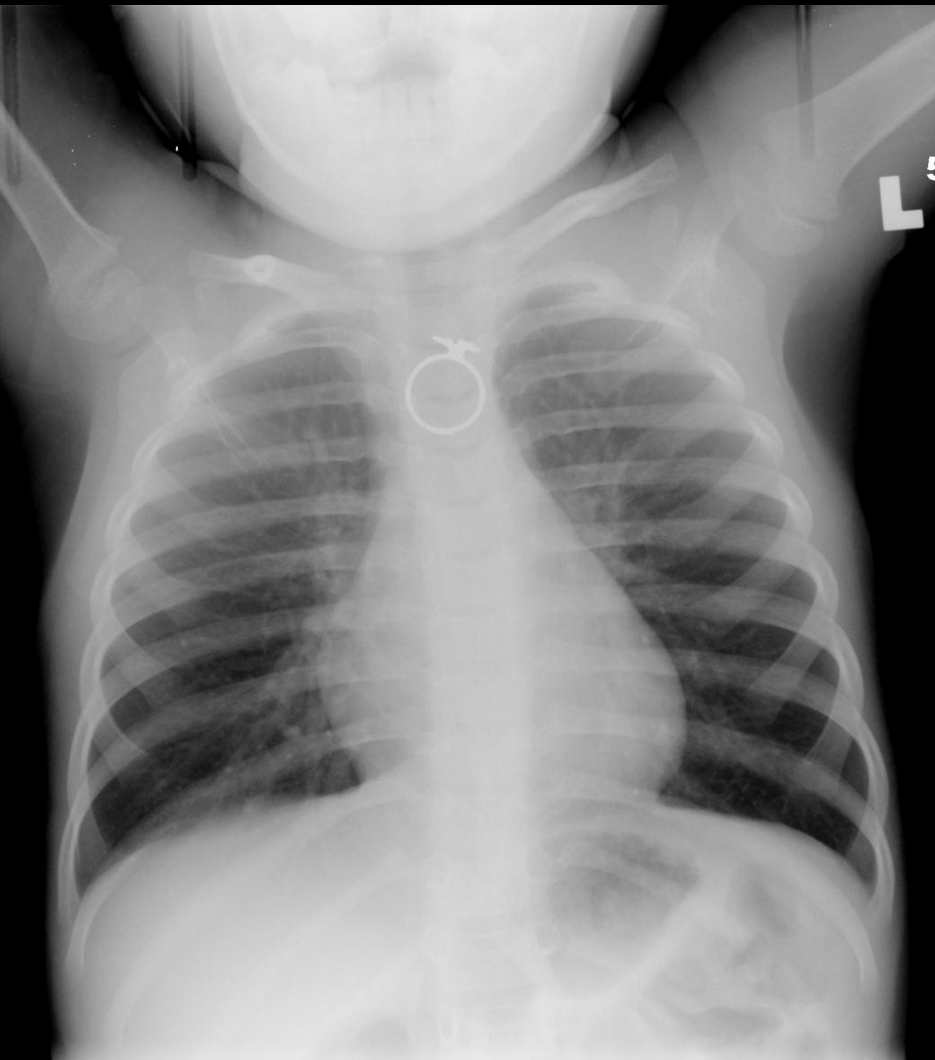


Hardware

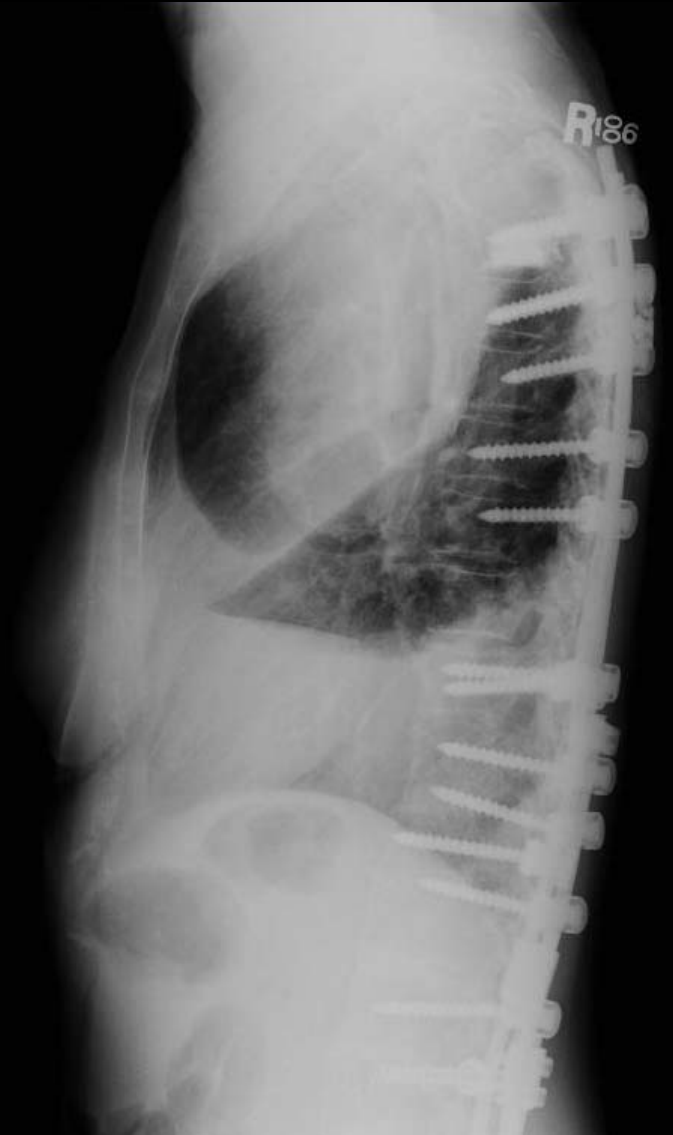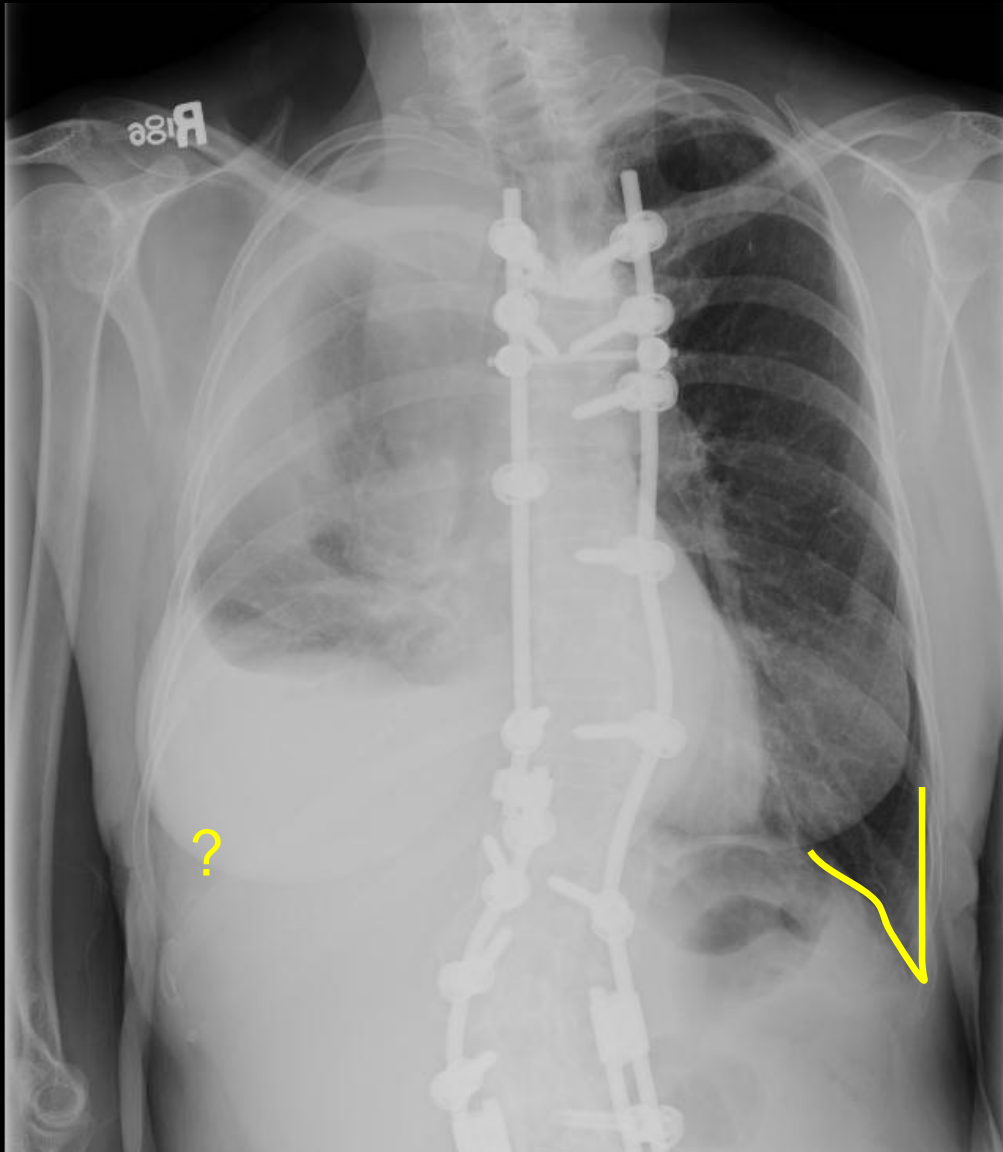
Internal Cardiac Defibrillator (ICD)



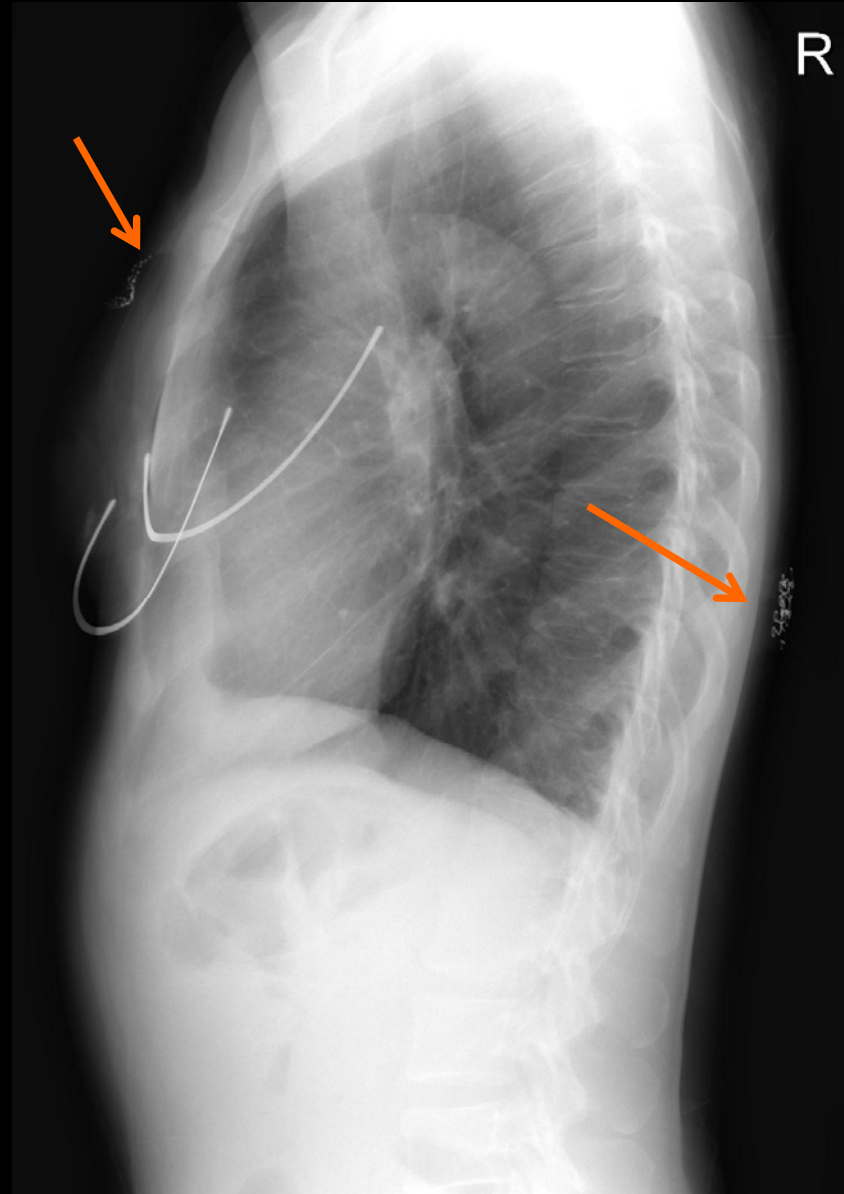
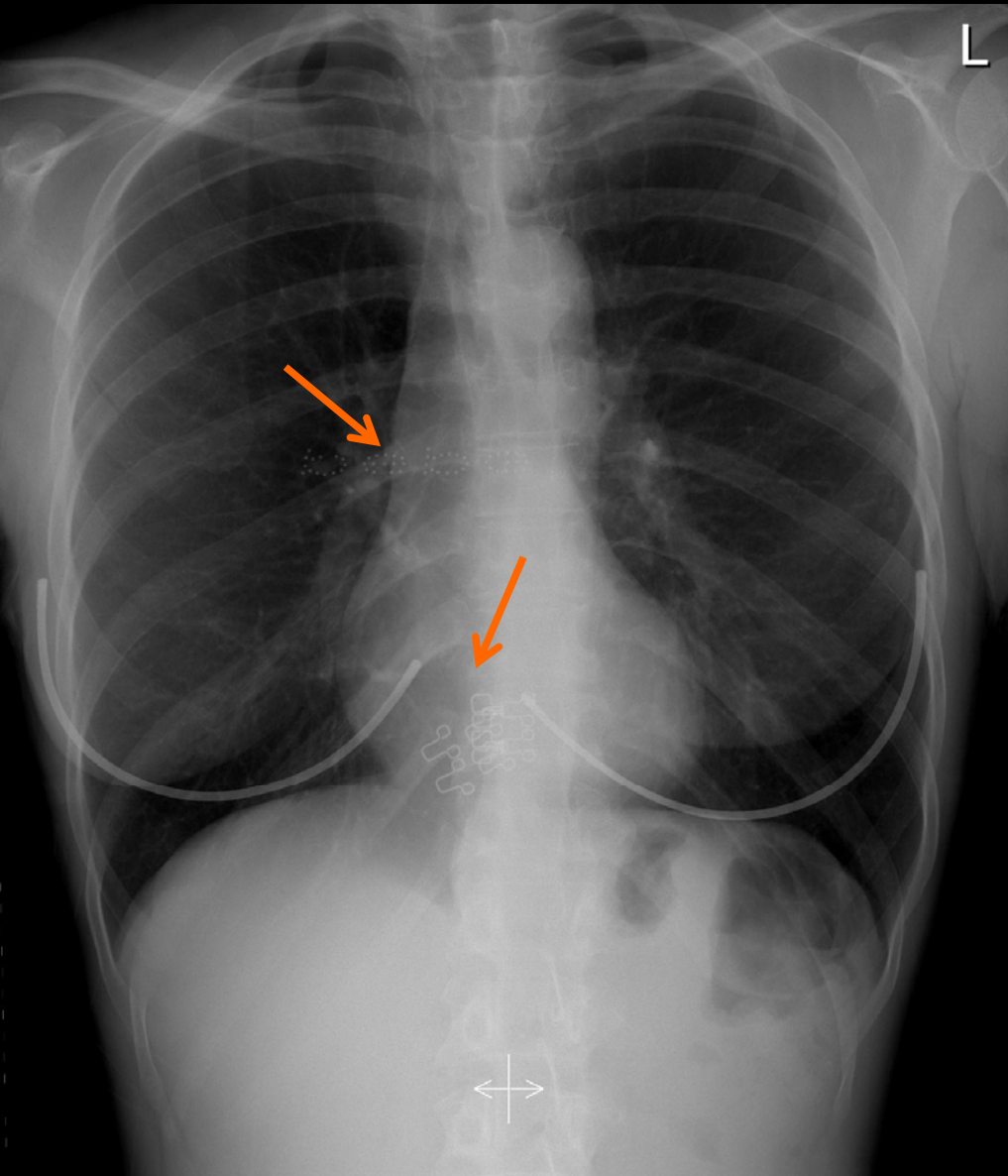
Missing Engagement Ring!



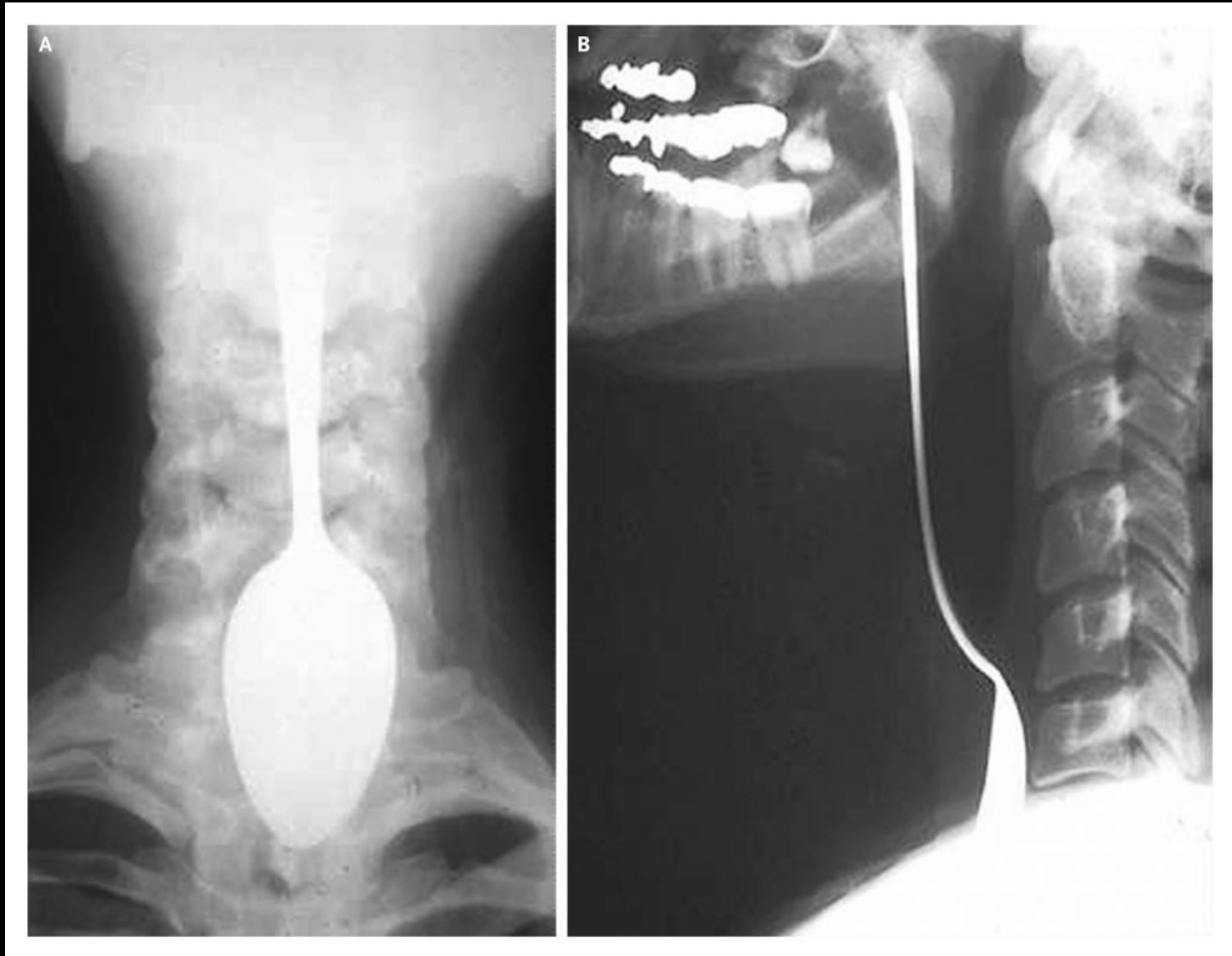
Spinal Fusion Surgery AND Right Pleural Effusion



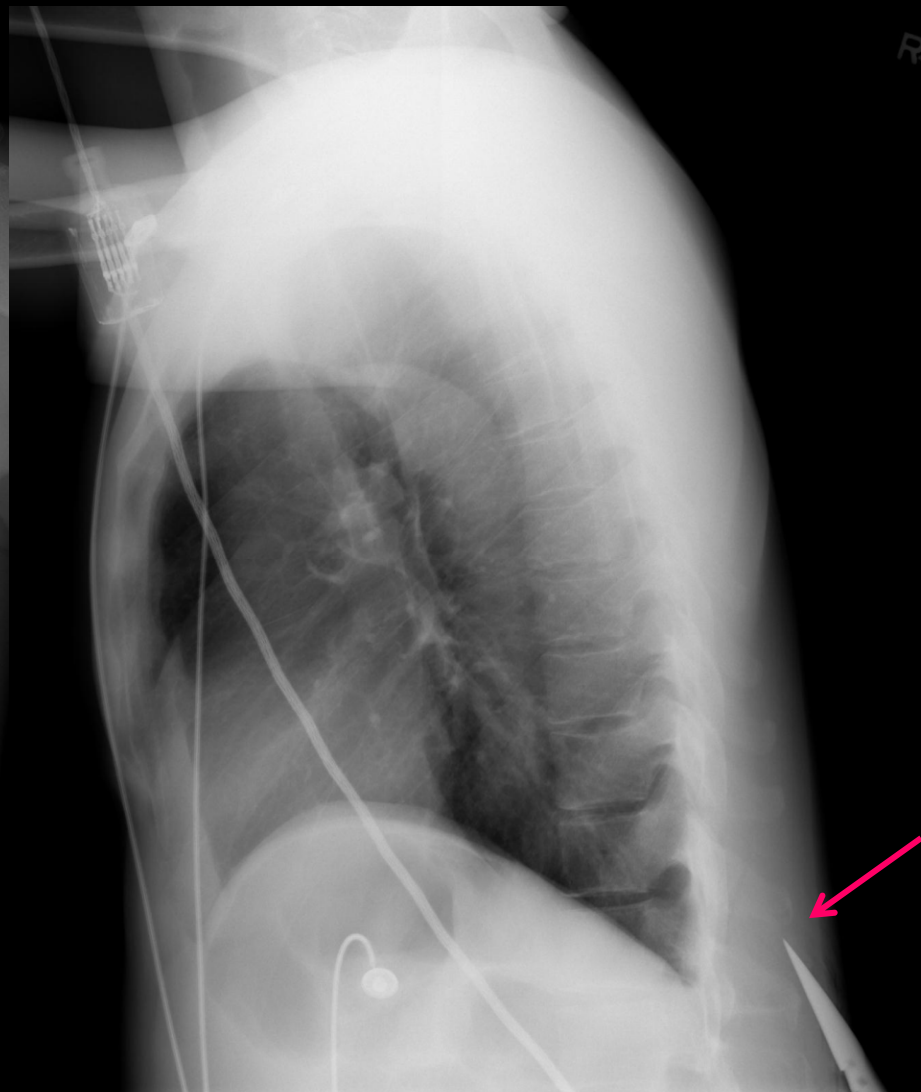
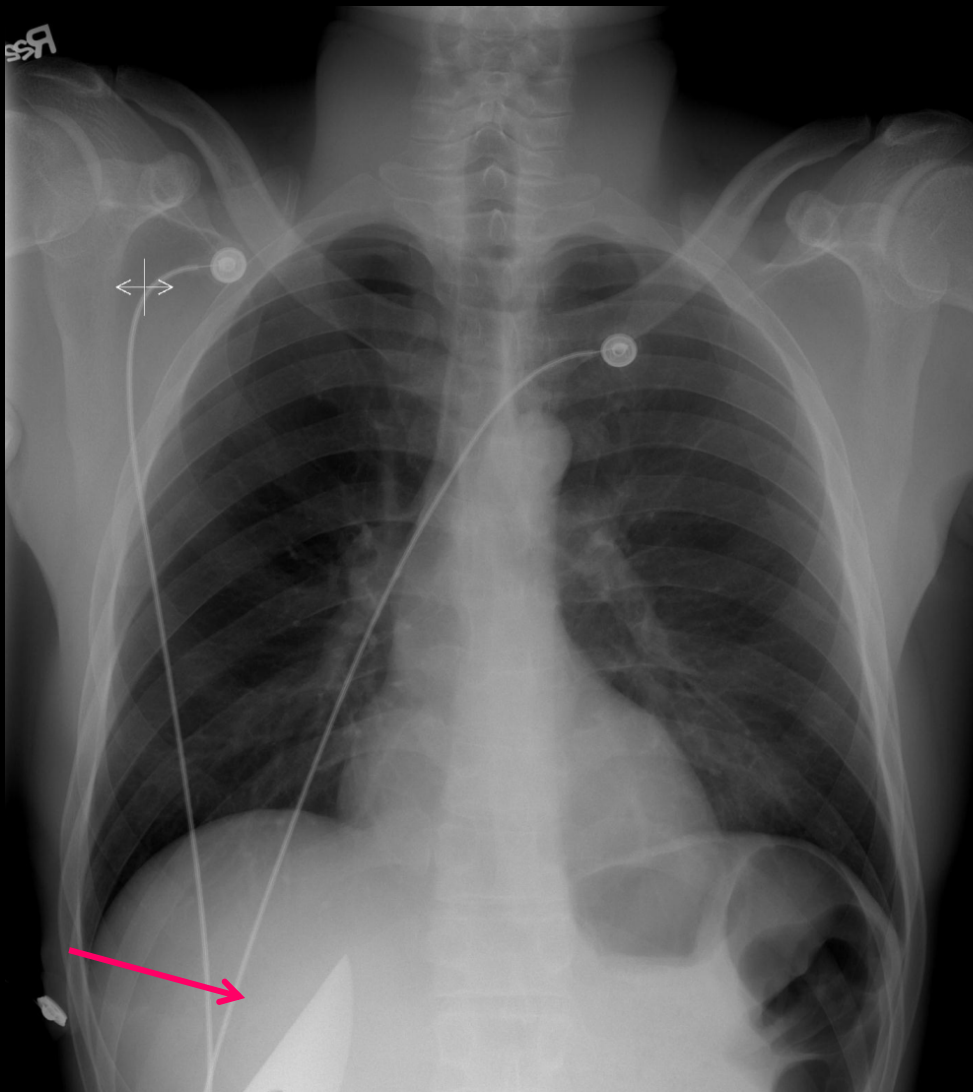
Clothing Artifact



NEJM Image of the Week

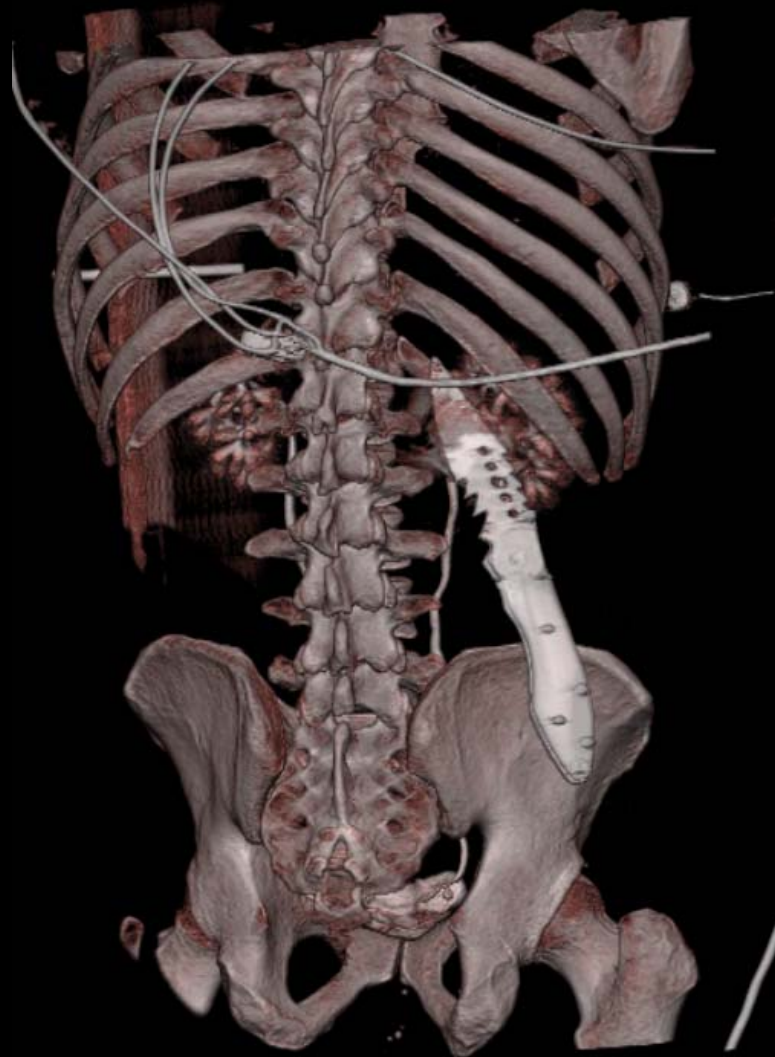
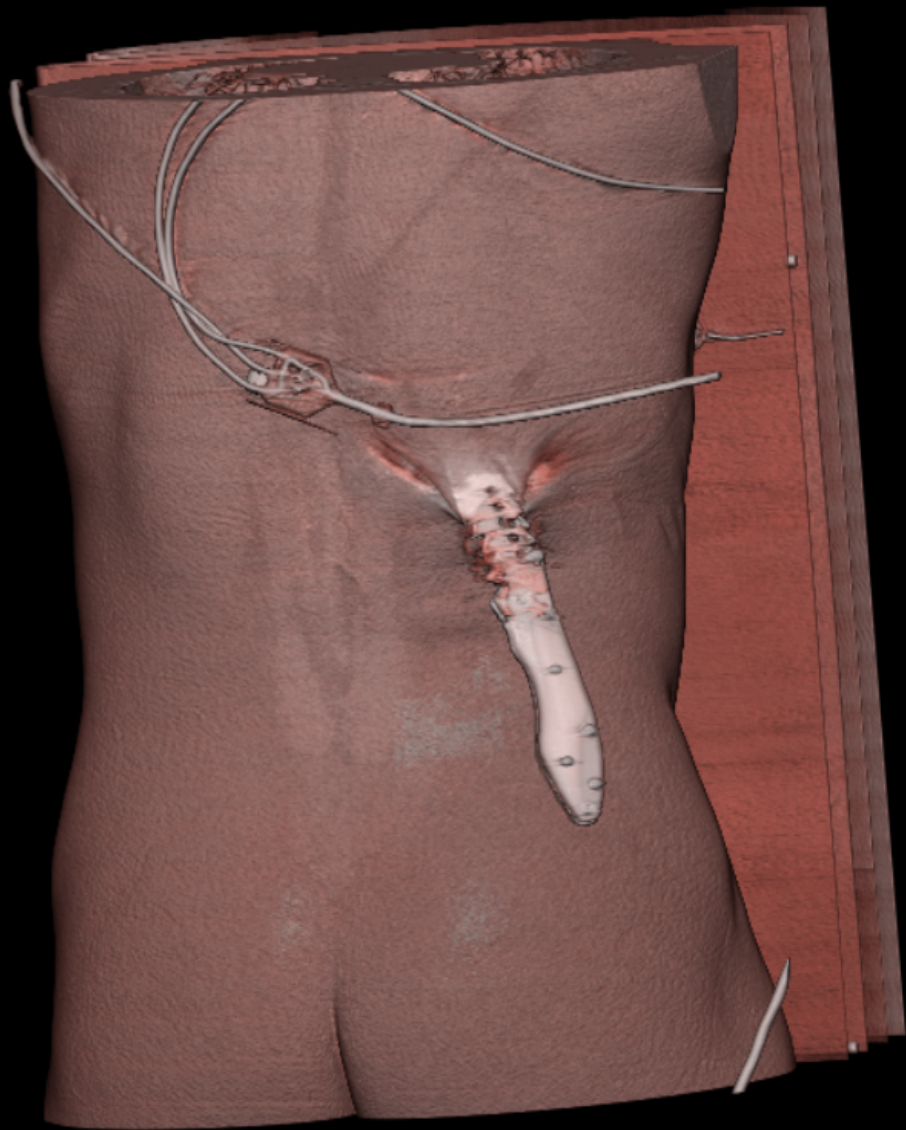

??????



Stab- Knife in Thorax

6



What are we looking at?

Airway

Effusions

Bones

Fields (Lung)

Cardiac

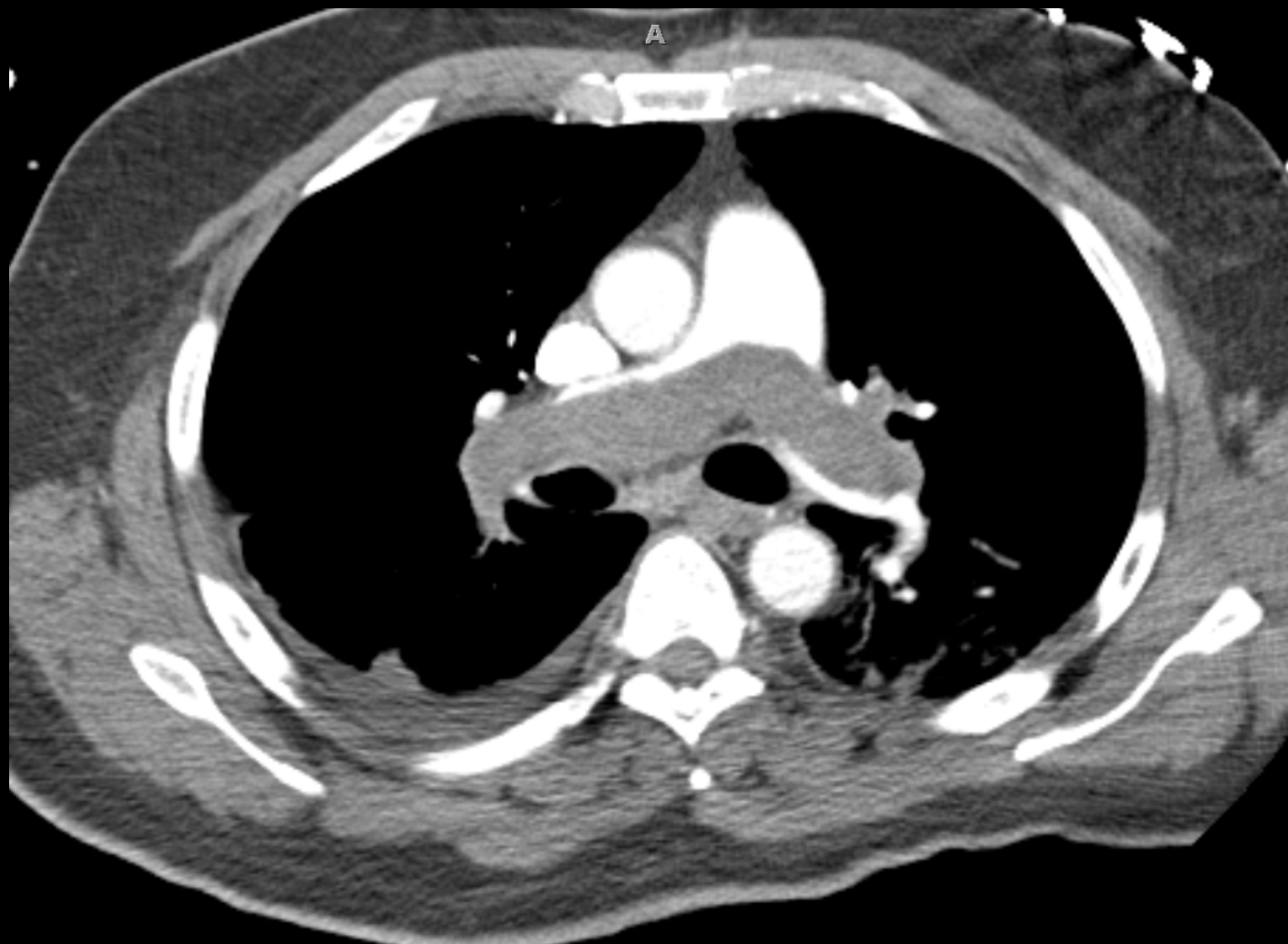
Gastric Bubble

Diaphragm

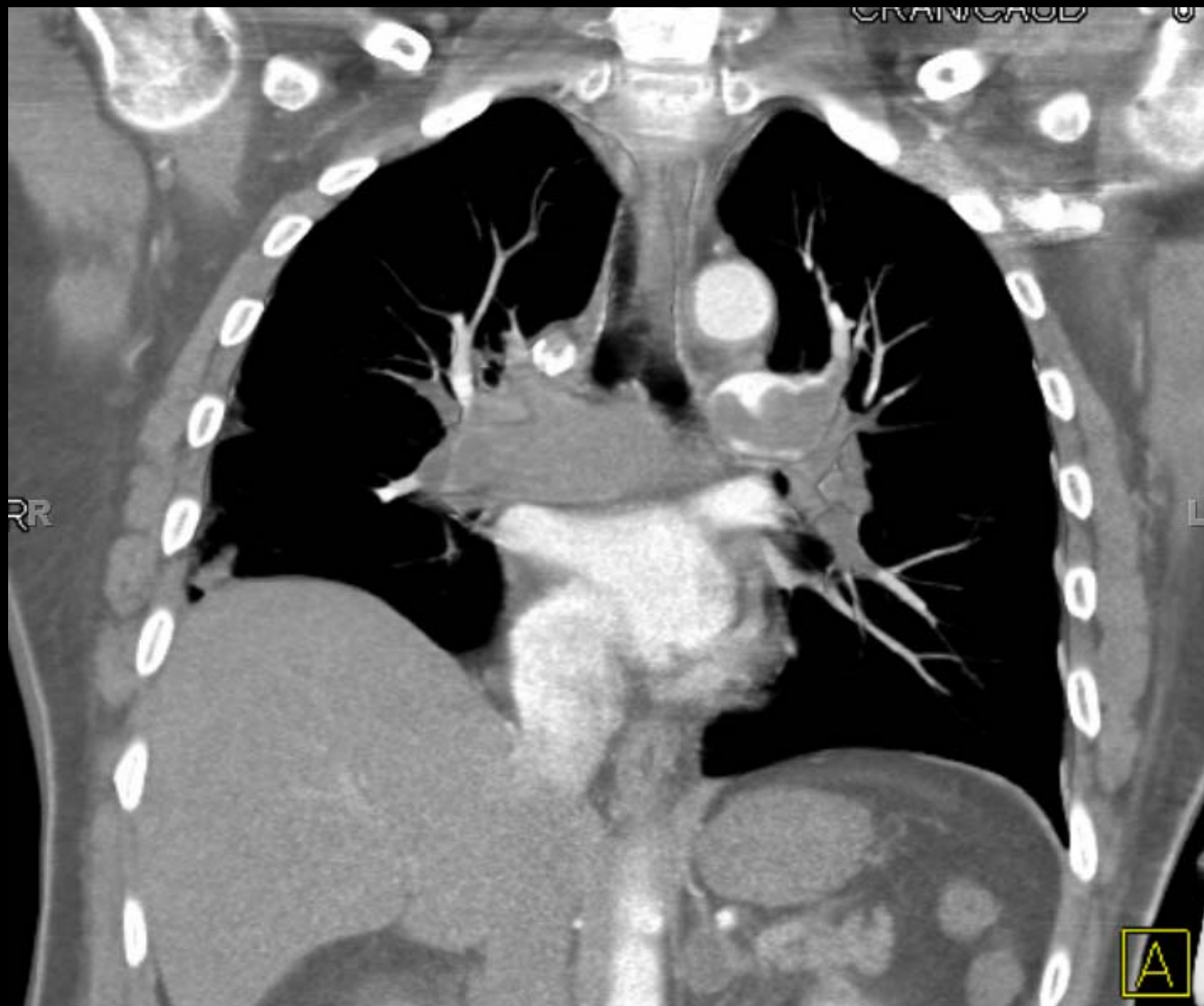
Hardware

What else can
radiologists
do in the
THORAX??

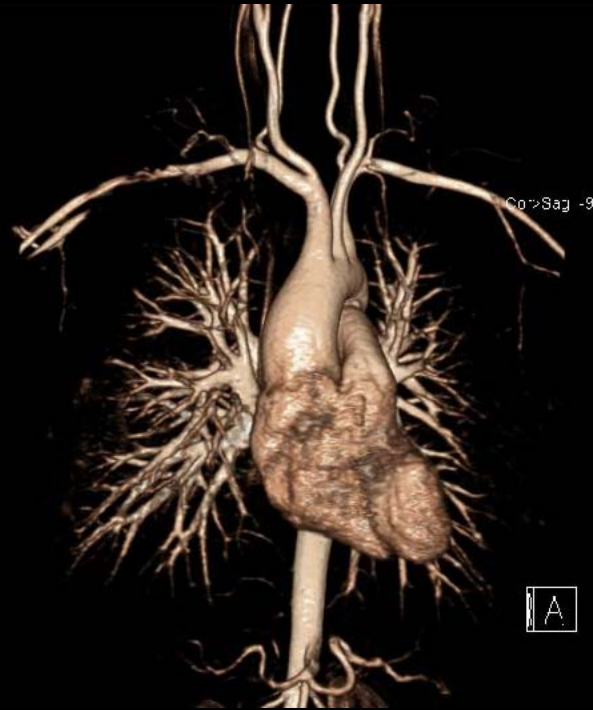
Chest CT - Pulmonary Embolism



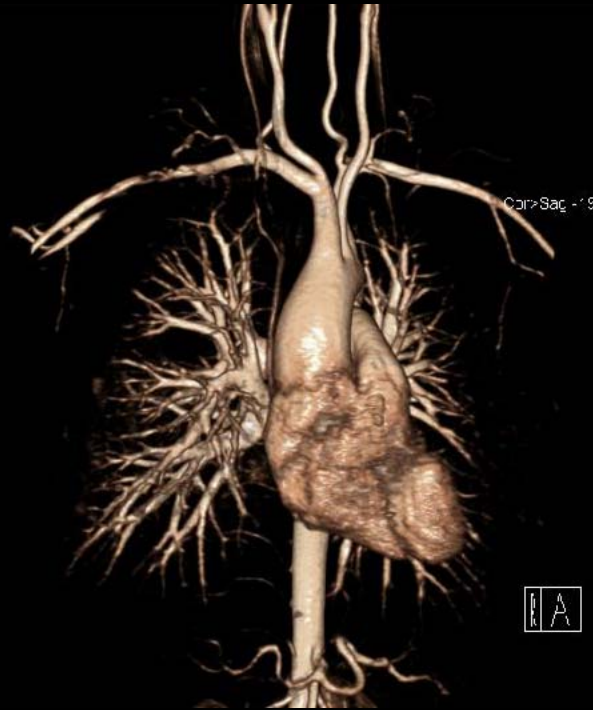
Chest CT - Pulmonary Embolism



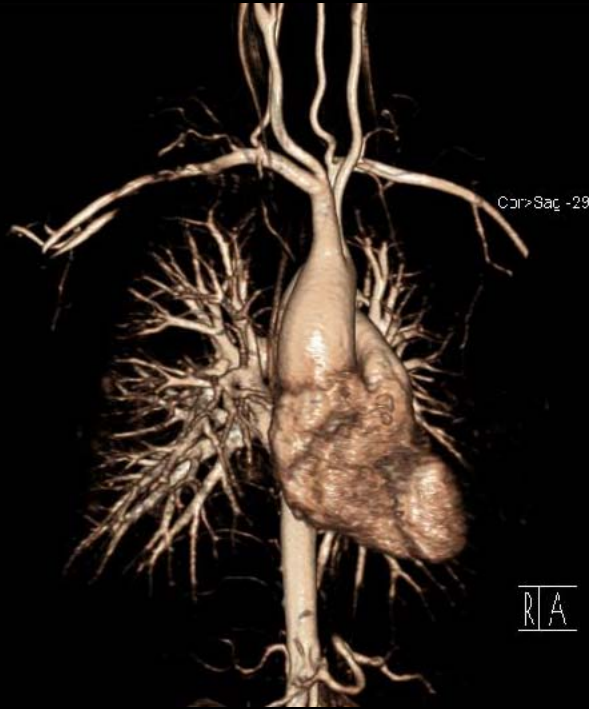Magnetic Resonance Angiography (MRA)



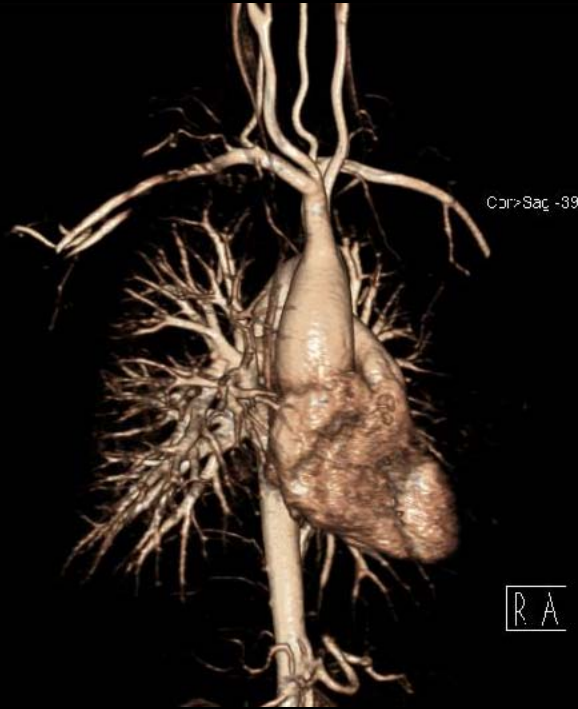Magnetic Resonance Angiography (MRA)



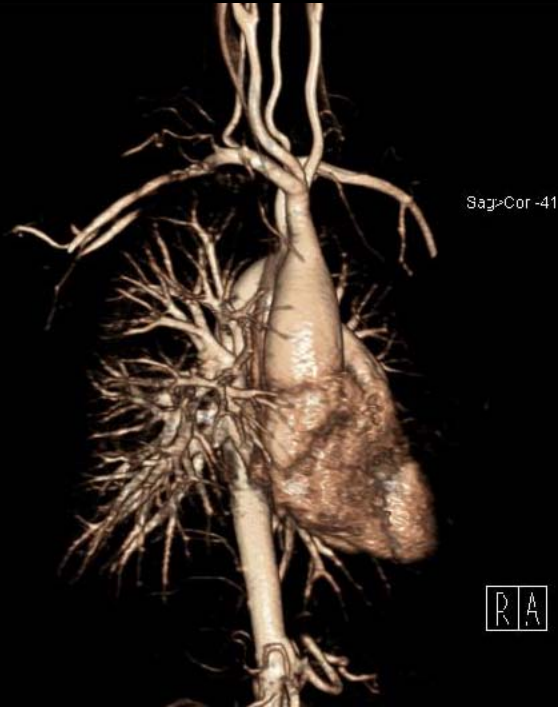Magnetic Resonance Angiography (MRA)



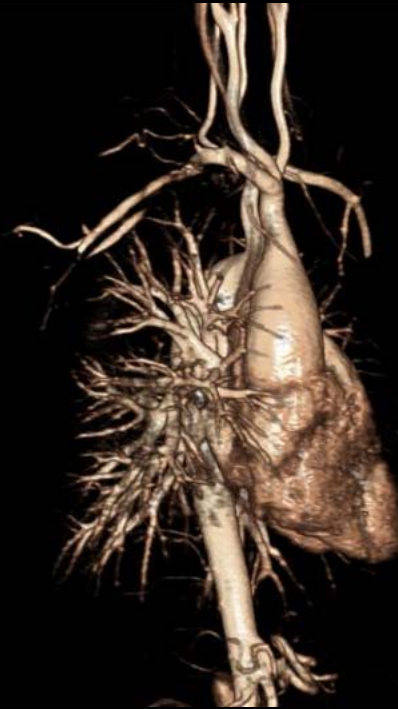Magnetic Resonance Angiography (MRA)



Magnetic Resonance Angiography (MRA)



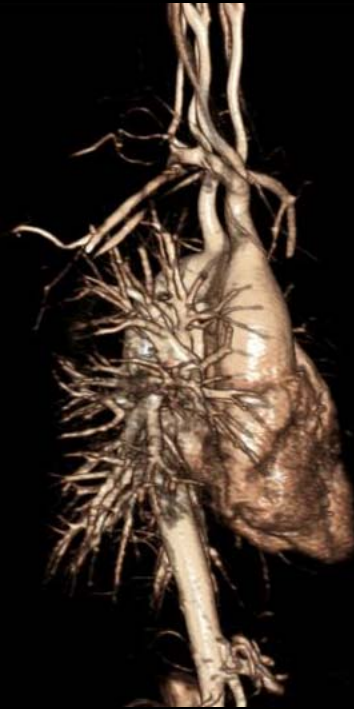Magnetic Resonance Angiography (MRA)



Sag-Cor-81

R | A

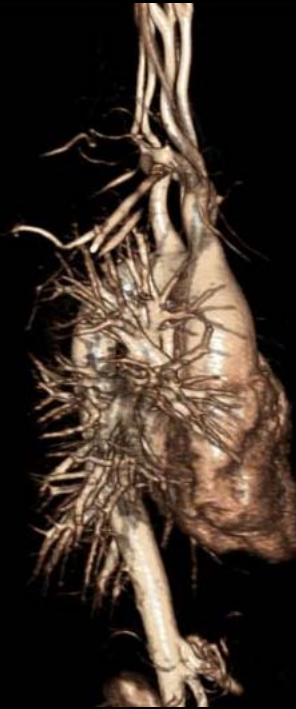Magnetic Resonance Angiography (MRA)



Sag>Cor -21

RA

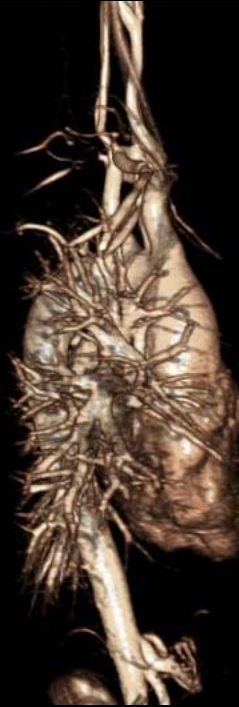Magnetic Resonance Angiography (MRA)



Sag>Cor -11

R

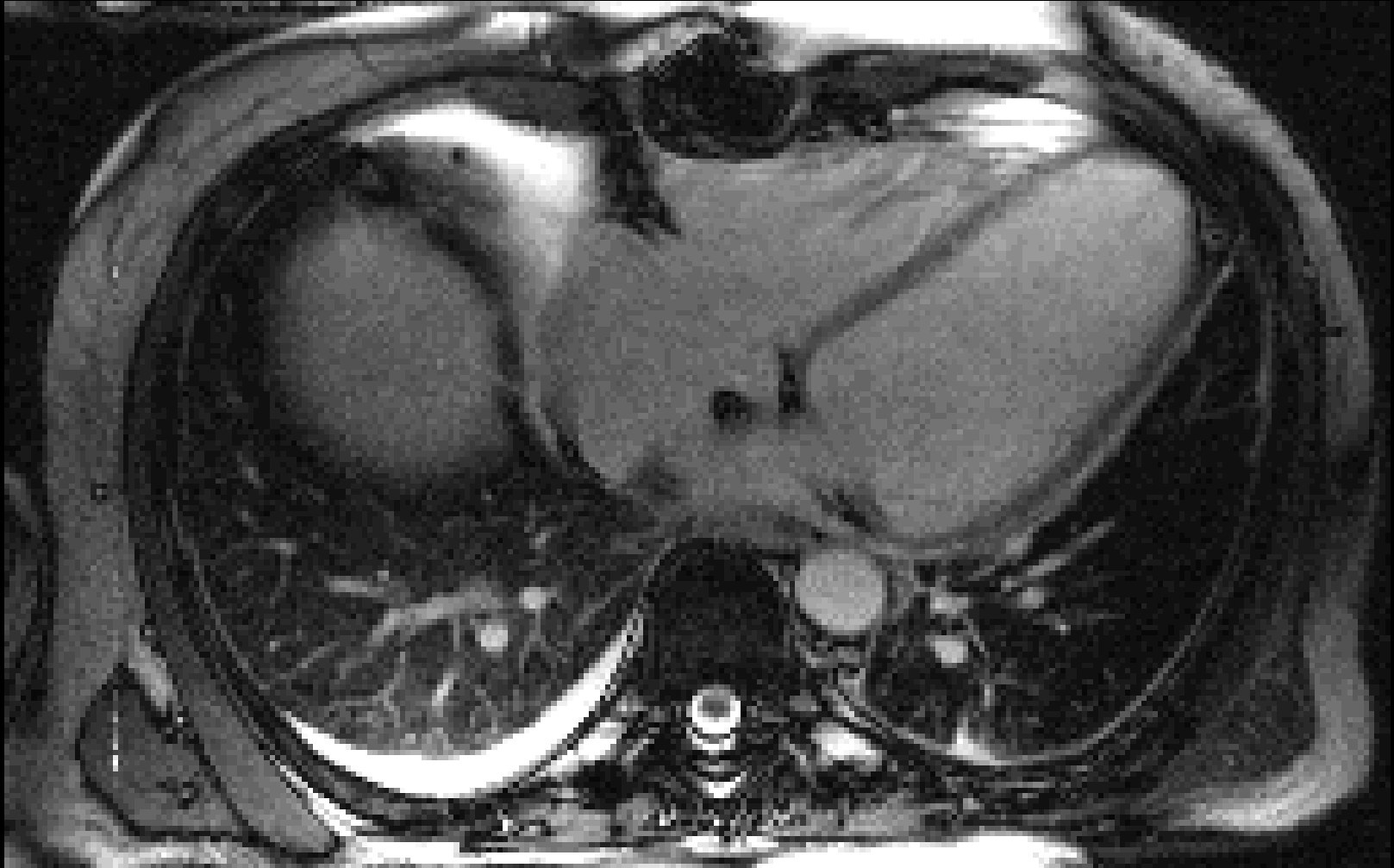
Magnetic Resonance Angiography (MRA)



Sag-Cor -1



Cardiac MRI



Take Home Points

- Know the ABC's of approaching a frontal chest film
- Start to understand the “black and whites” of xray imaging
- Ideal Study is PA/lateral chest films

Welcome to Hopkins!



Questions?

chris_long@jhmi.edu